

Minimally invasive & novel Therapeutics (MINT) conference '22

Paraduodenal Pancreatitis, The Disease with a Hundred Names

Enrique de-Madaria, MD PhD

Alicante, Spain

Cystic dystrophy of the duodenal wall

Adenomyoma

Groove pancreatitis

Pancreatic duodenal hamartoma

Paraduodenal pancreatitis

INTRODUCTION



Potet & Duclert

Cystic dystrophy on aberrant pancreas of the duodenal wall

Becker

Groove pancreatitis

Adsay & Zamboni

Paraduodenal pancreatitis

Pancreatic duodenal hamartoma

INTRODUCTION



HARVARD
MEDICAL SCHOOL




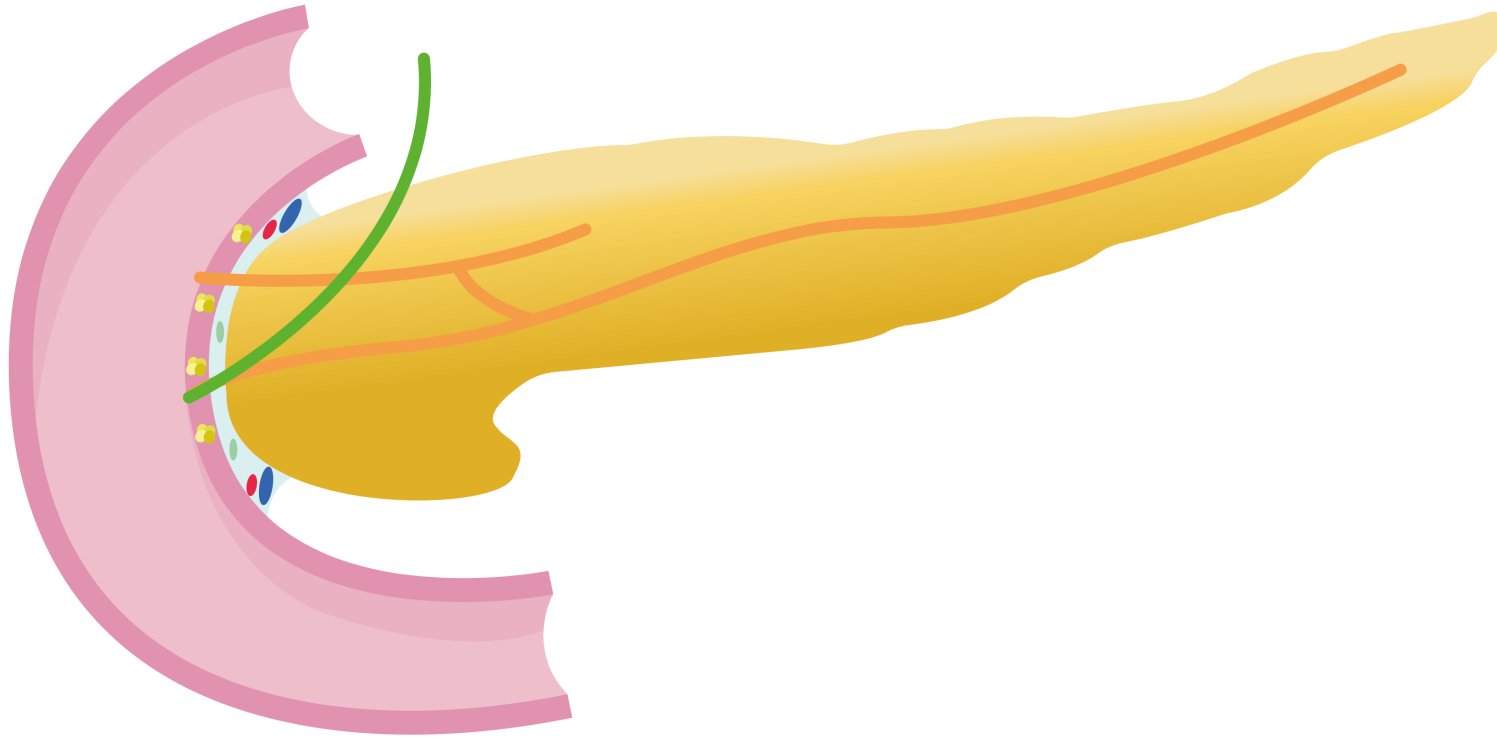
Hospital General
Universitario Dr. Balmis



ISABIAL
INSTITUTO
DE INVESTIGACIÓN
SANITARIA Y BIOMÉDICA
DE ALICANTE



UNIVERSITAS
Miguel Hernández



E. de-Madaria

E. de-Madaria

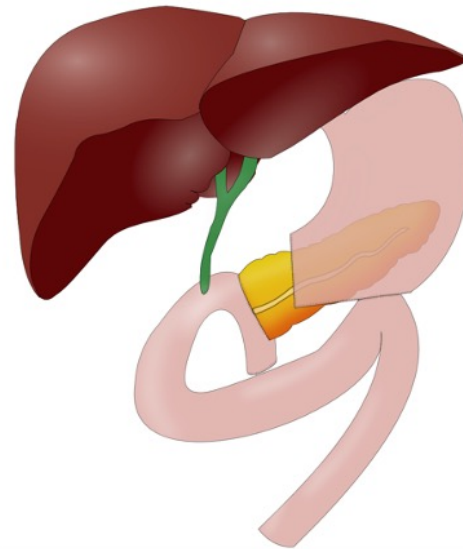
INTRODUCTION



Volker Becker

Int. J. Pancreatol 1991

600 Whipples
for chronic
pancreatitis

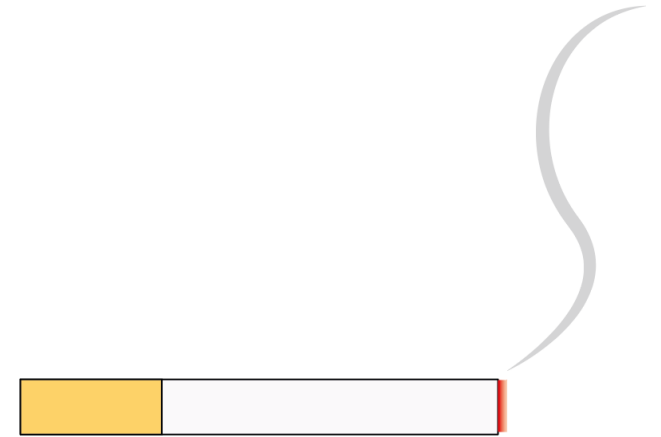
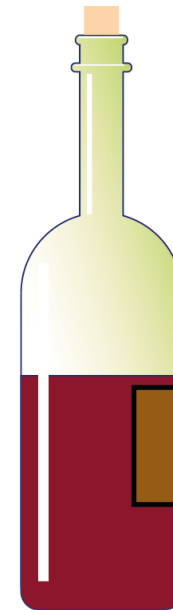
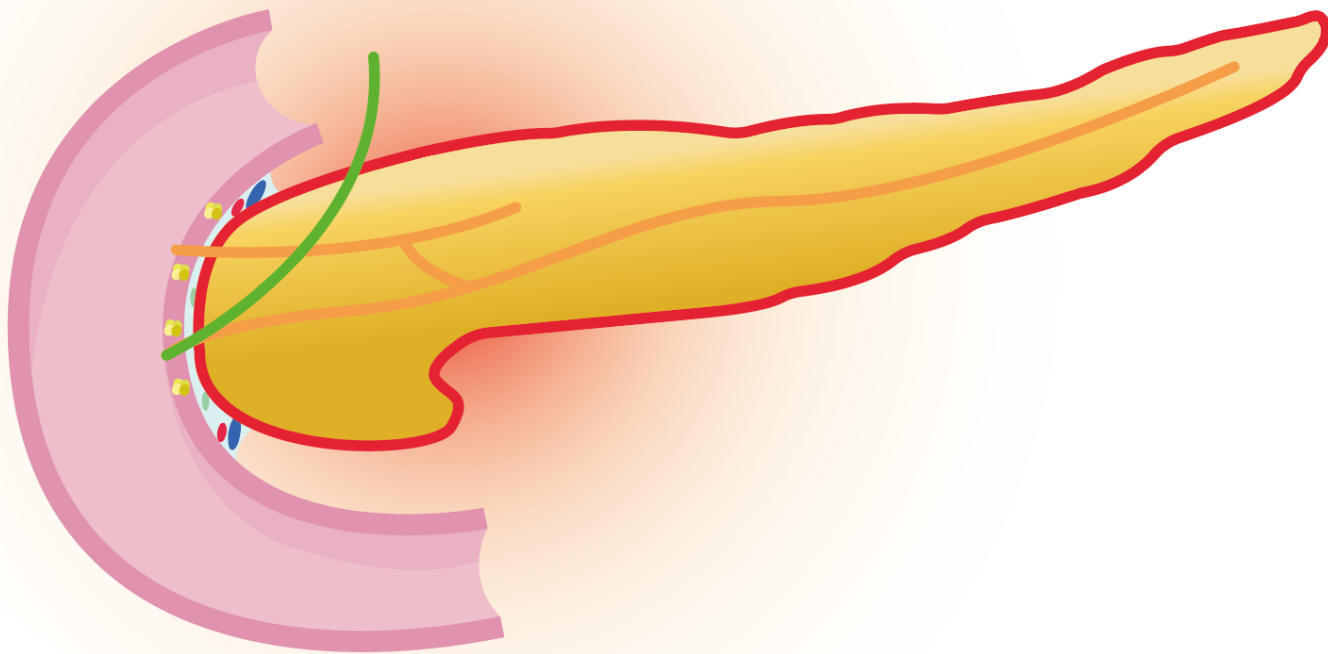


20% GROOVE INVOLVEMENT
2% pure groove involvement 7%
segmental pancreatitis of the
head with groove involvement
11% chronic pancreatitis with
groove involvement

50% with duodenal cysts

FREQUENCY

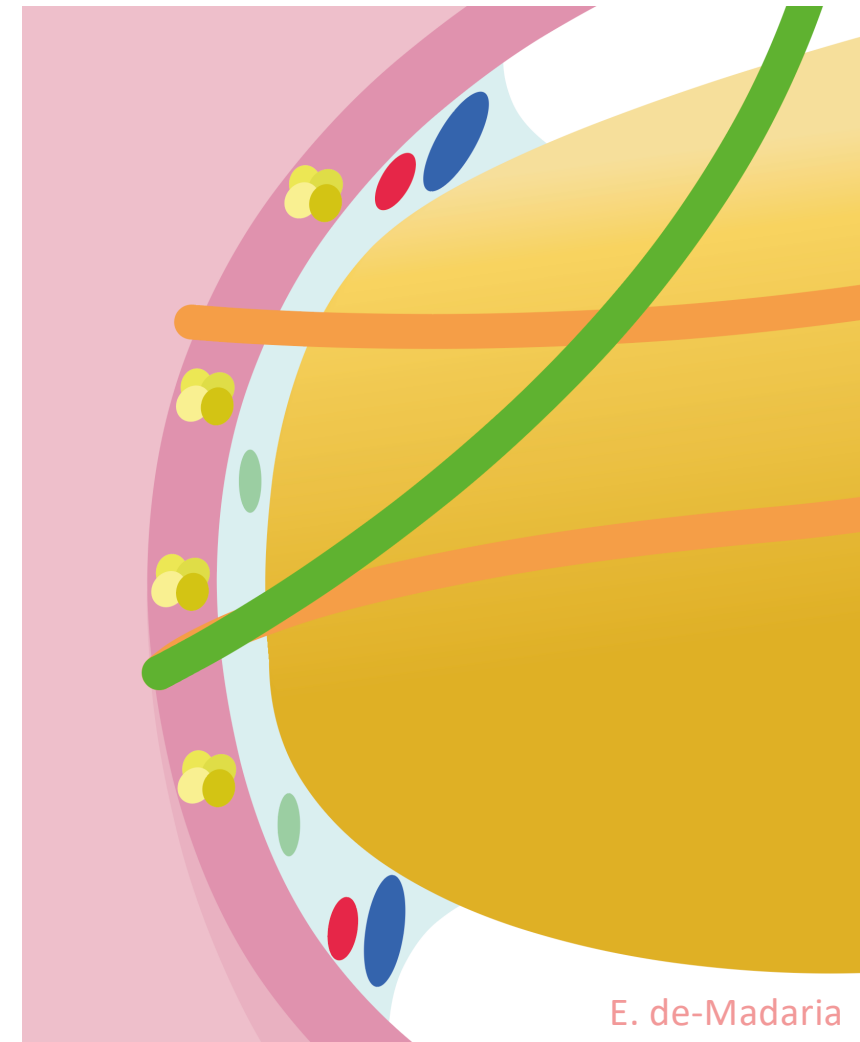
Males, 5th decade



E. de-Madaria

ETIOLOGY & PATHOPHYSIOLOGY

According to 1 single center study 0.18% of all pathology samples have digestive wall heterotopic pancreatic tissue, in 25% cases in duodenum/proximal jejunum





HARVARD
MEDICAL SCHOOL



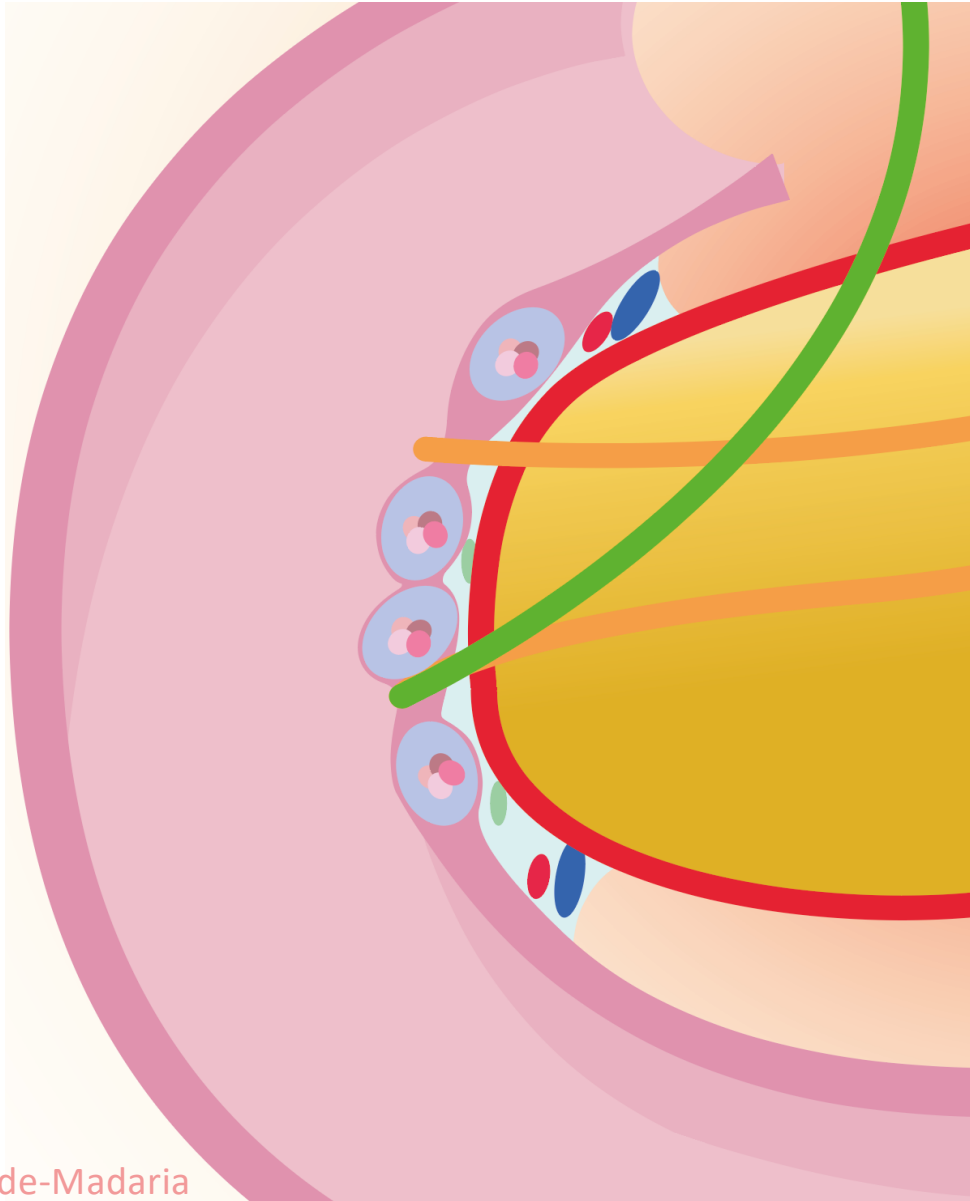
Hospital General
Universitario Dr. Balmis



ISABIAL
INSTITUTO
DE INVESTIGACIÓN
SANITARIA Y BIOMÉDICA
DE ALICANTE



UNIVERSITAS
Miguel Hernández

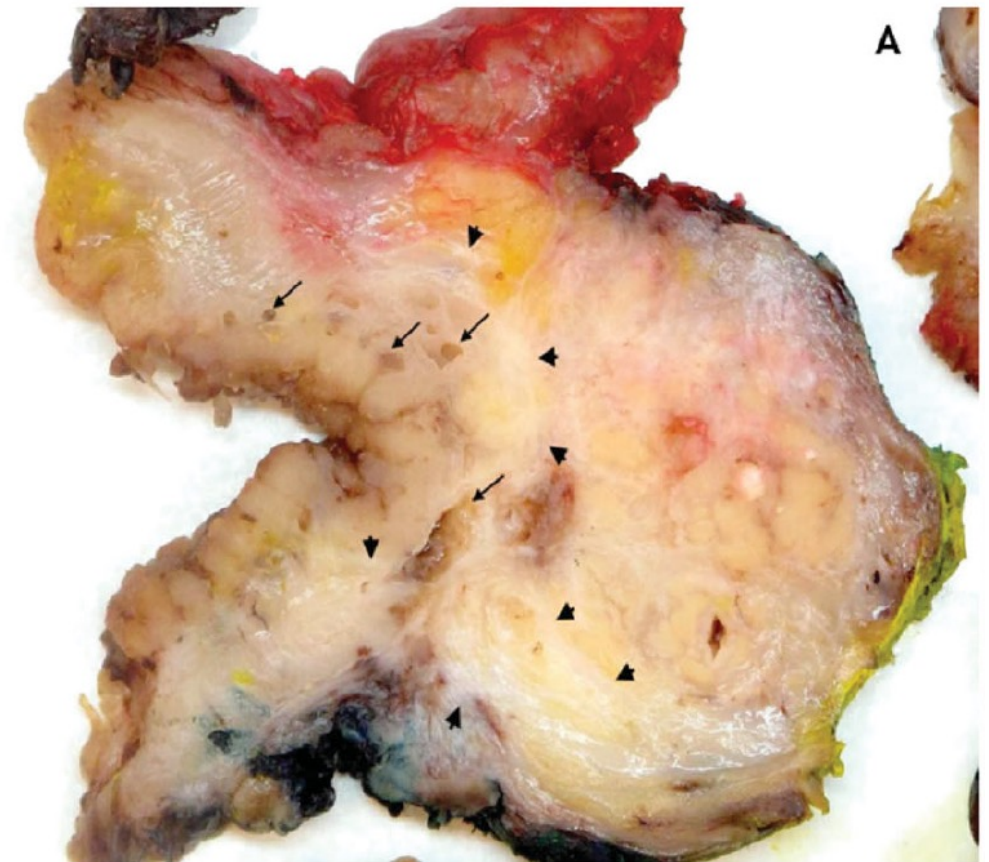
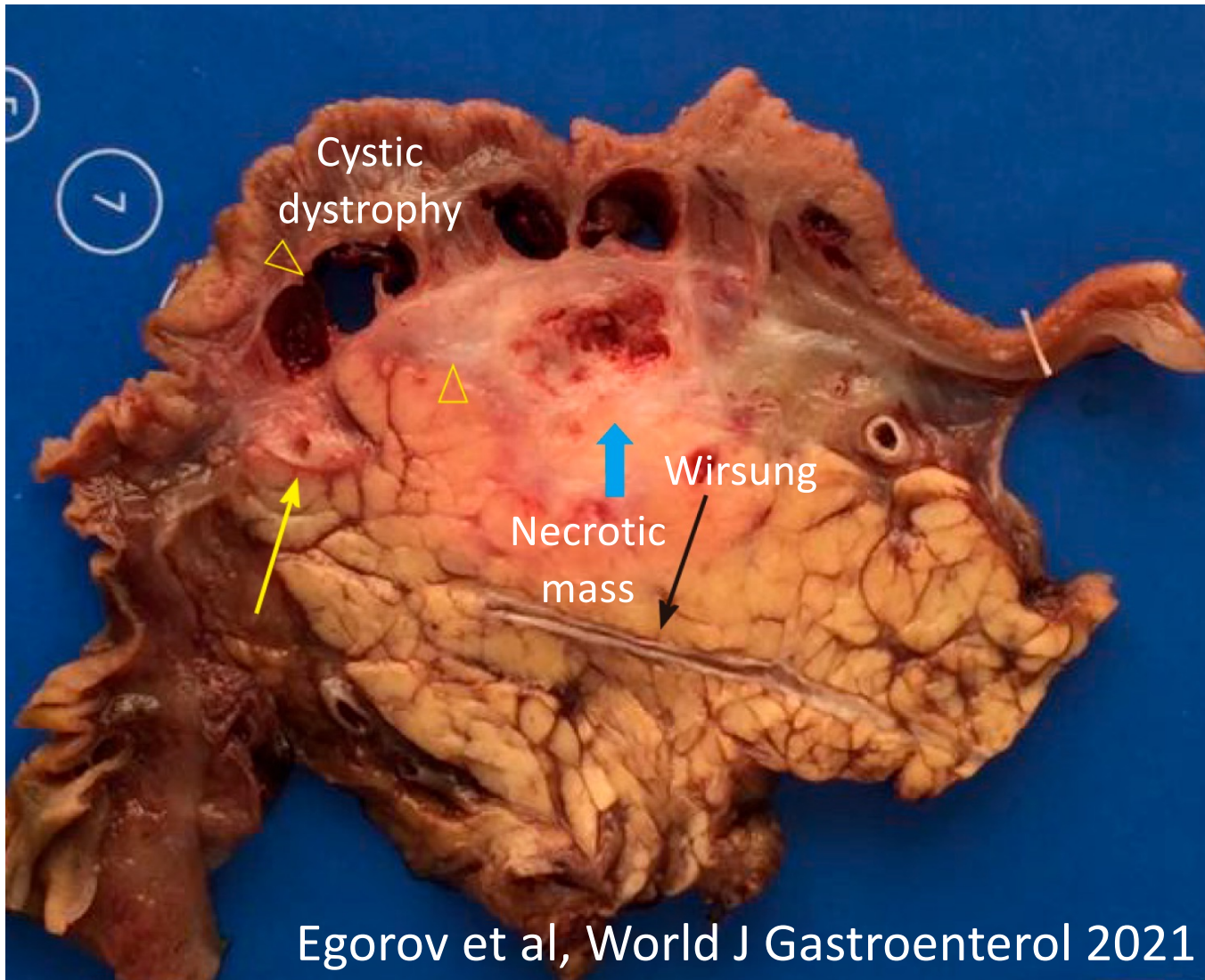


E. de-Madaria



E. de-Madaria

Cystic dystrophy on aberrant
pancreas of the duodenal wall
ETIOLOGY & PATHOPHYSIOLOGY



Vujasinovic [...] Verbeke, Scand J
Gastroenterol 2022 (Picture from C. Verbeke)

PATHOLOGY

With permission



HARVARD
MEDICAL SCHOOL



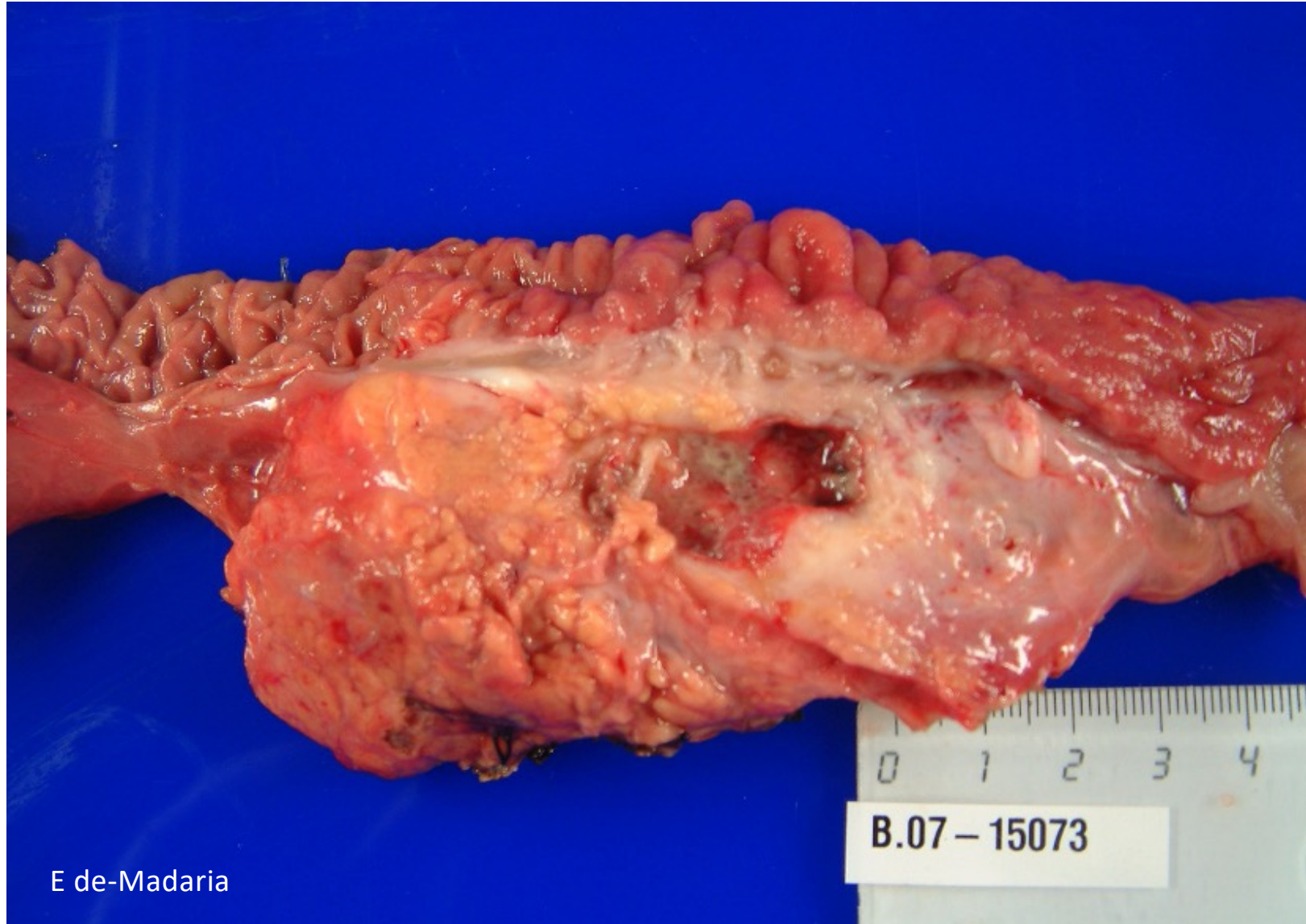Hospital General
Universitario Dr. Balmis



ISABIAL
INSTITUTO
DE INVESTIGACIÓN
SANITARIA Y BIOMÉDICA
DE ALICANTE



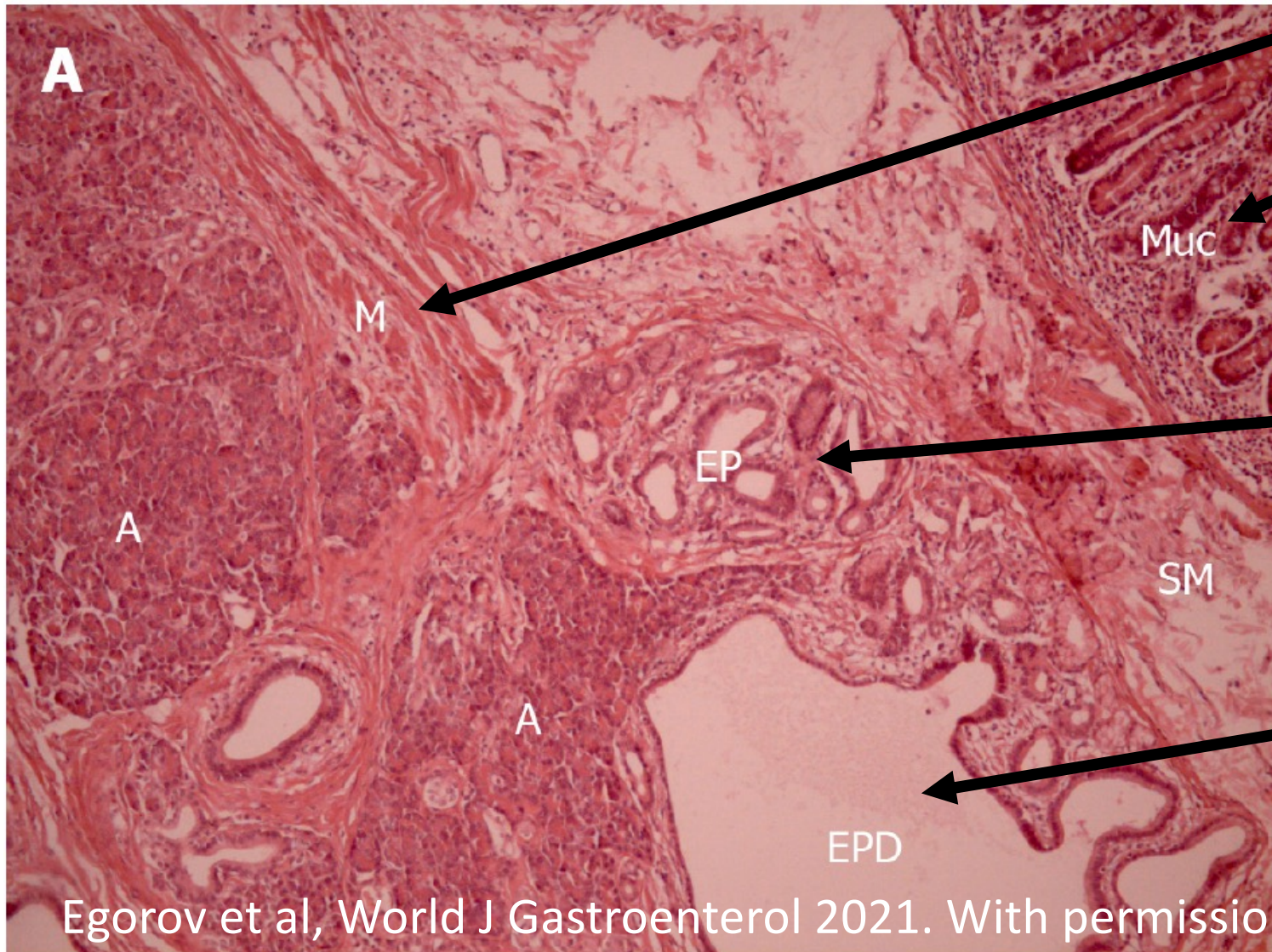
UNIVERSITAS
Miguel Hernández



E de-Madaria

B.07 - 15073

PATHOLOGY



Duodenal muscle layer

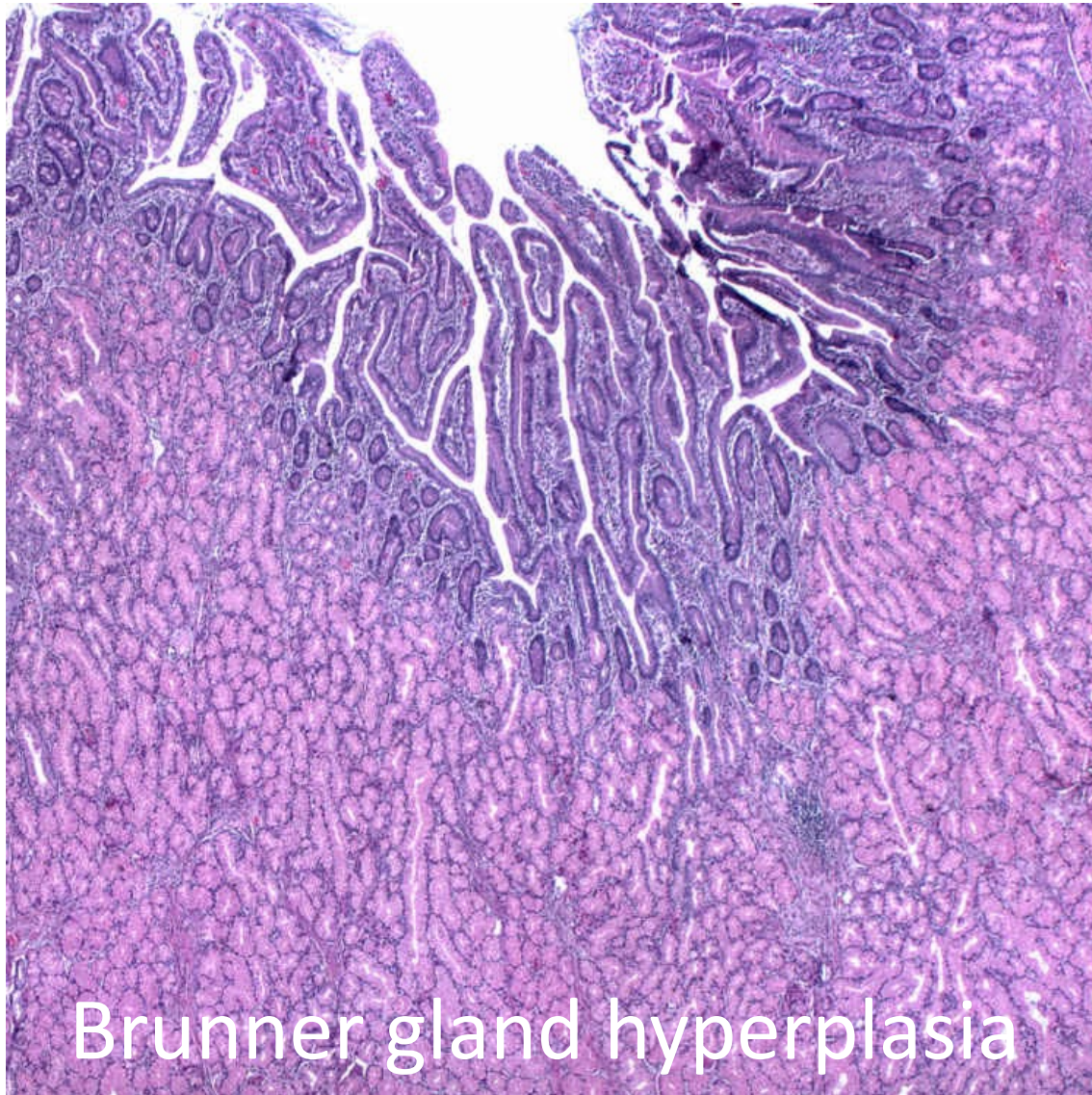
Duodenal mucosa

Ectopic pancreatic tissue

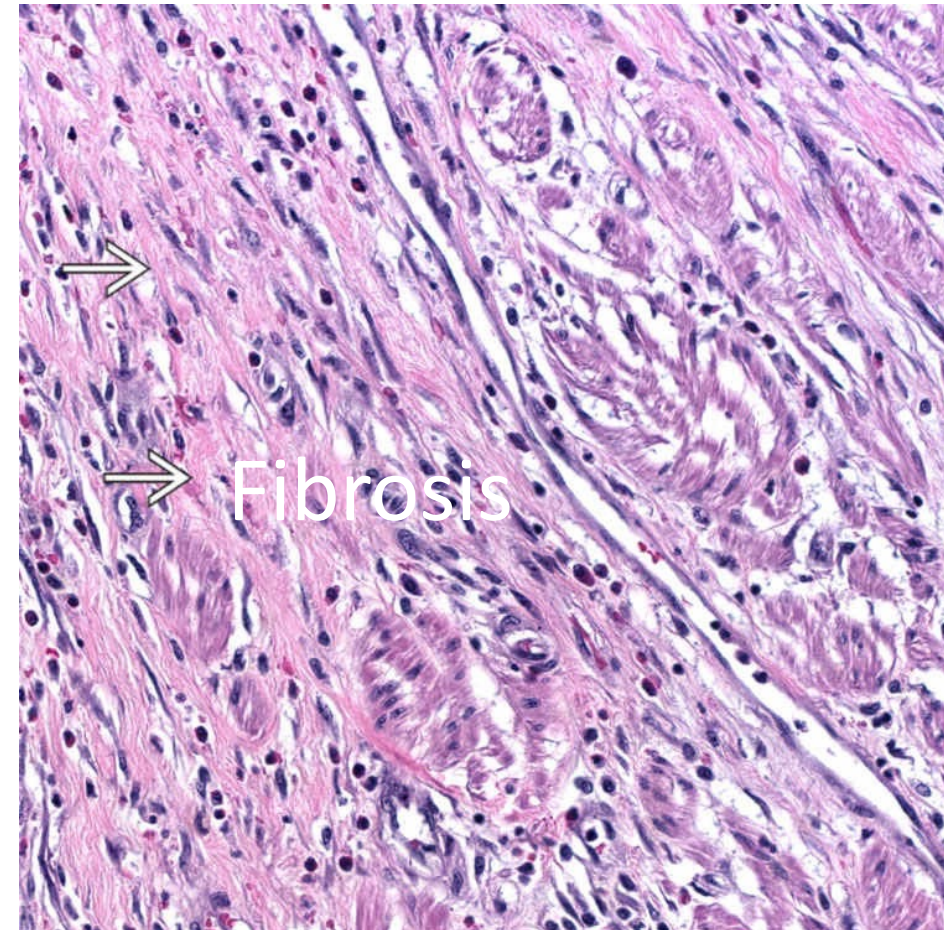
Dilated ectopic
pancreatic duct

PATHOLOGY

Egorov et al, World J Gastroenterol 2021. With permission



Brunner gland hyperplasia



Fibrosis

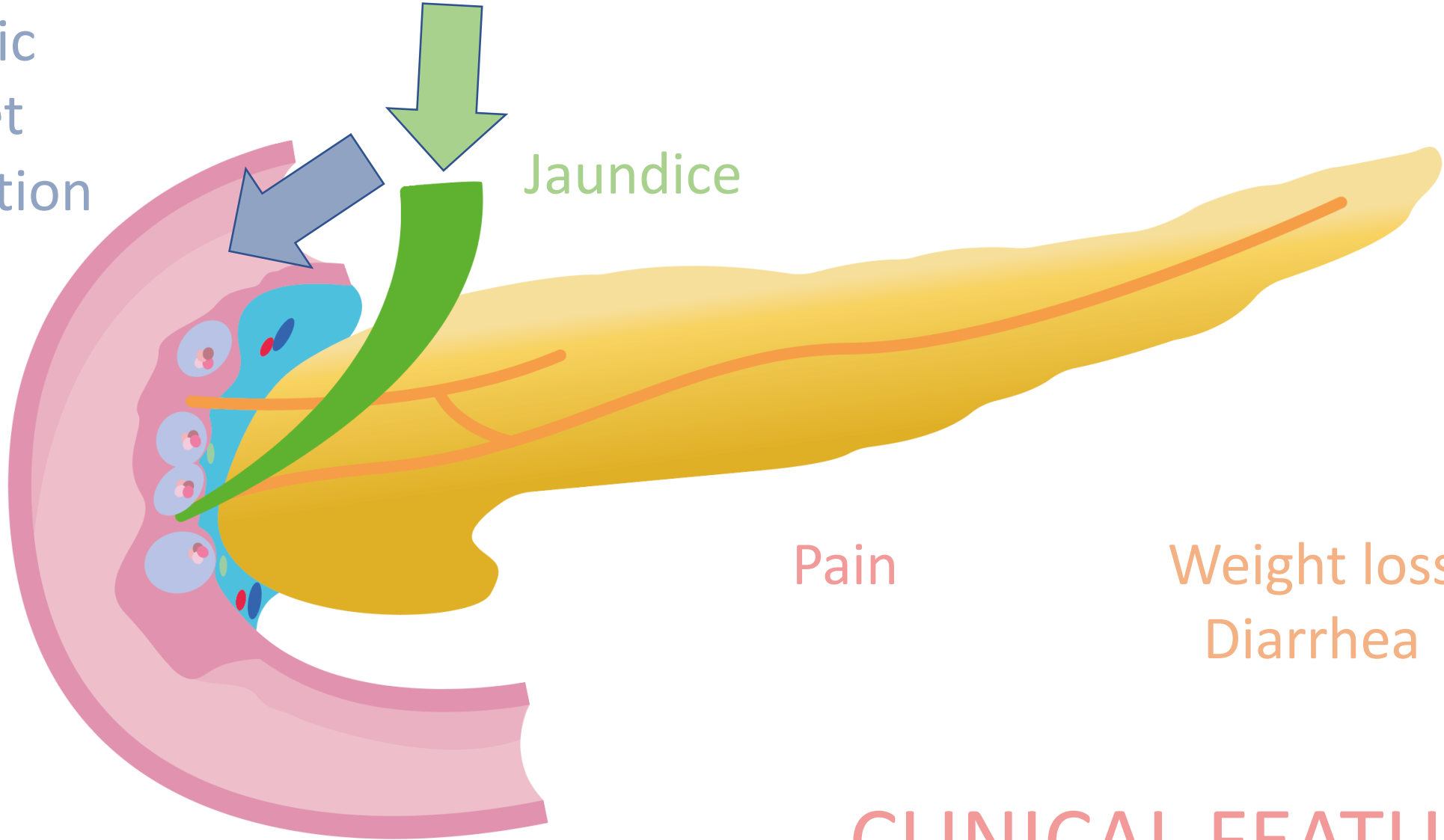
Gastric
outlet
obstruction

Jaundice

Pain

Weight loss
Diarrhea

CLINICAL FEATURES





HARVARD
MEDICAL SCHOOL



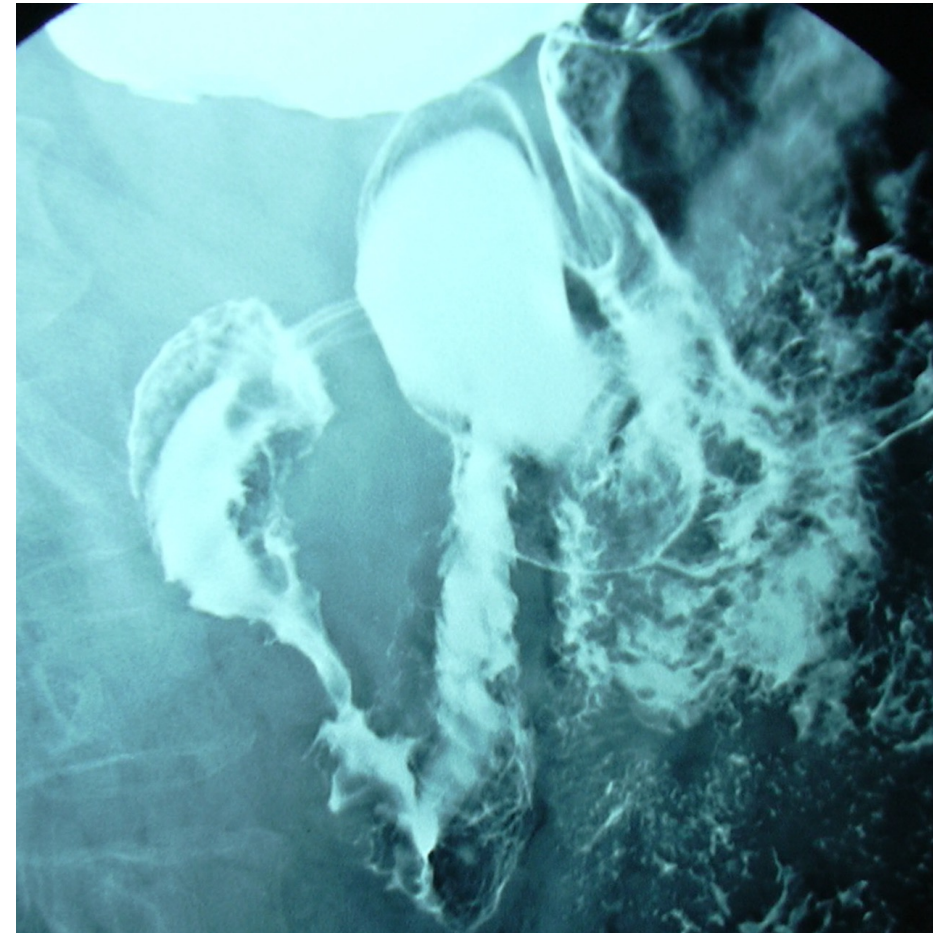
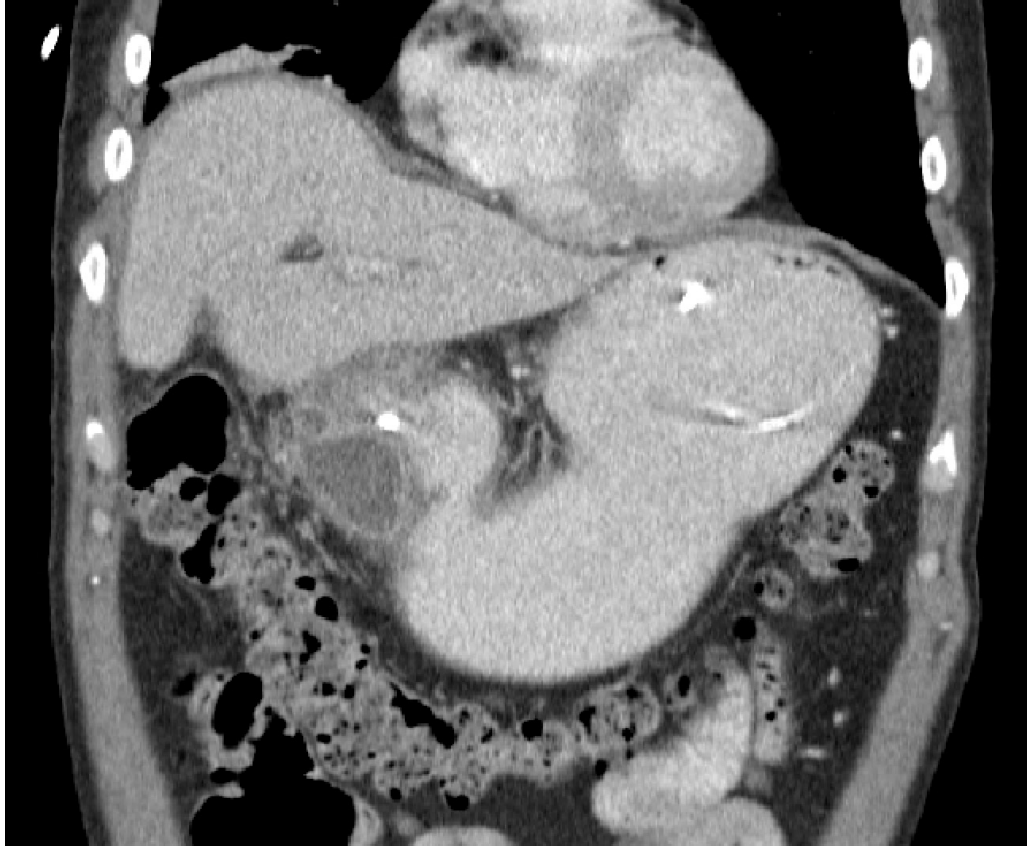Hospital General
Universitario Dr. Balmis



ISABIAL
INSTITUTO
DE INVESTIGACIÓN
SANITARIA Y BIOMÉDICA
DE ALICANTE

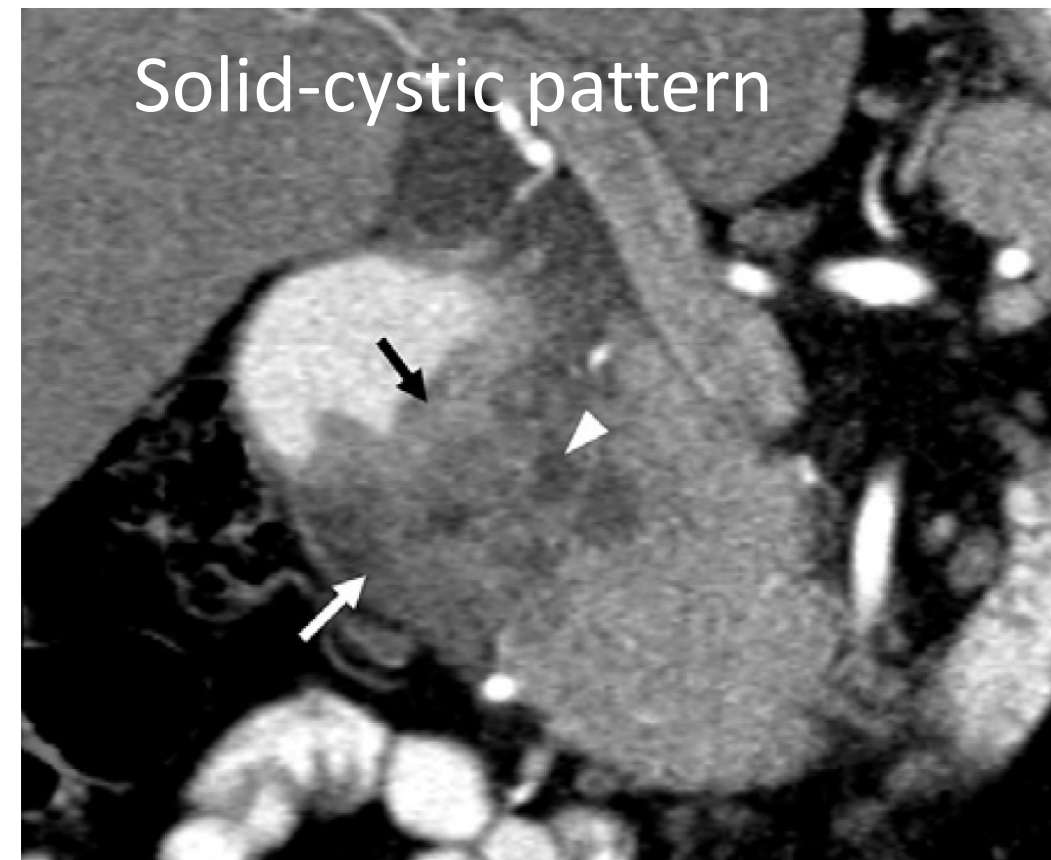
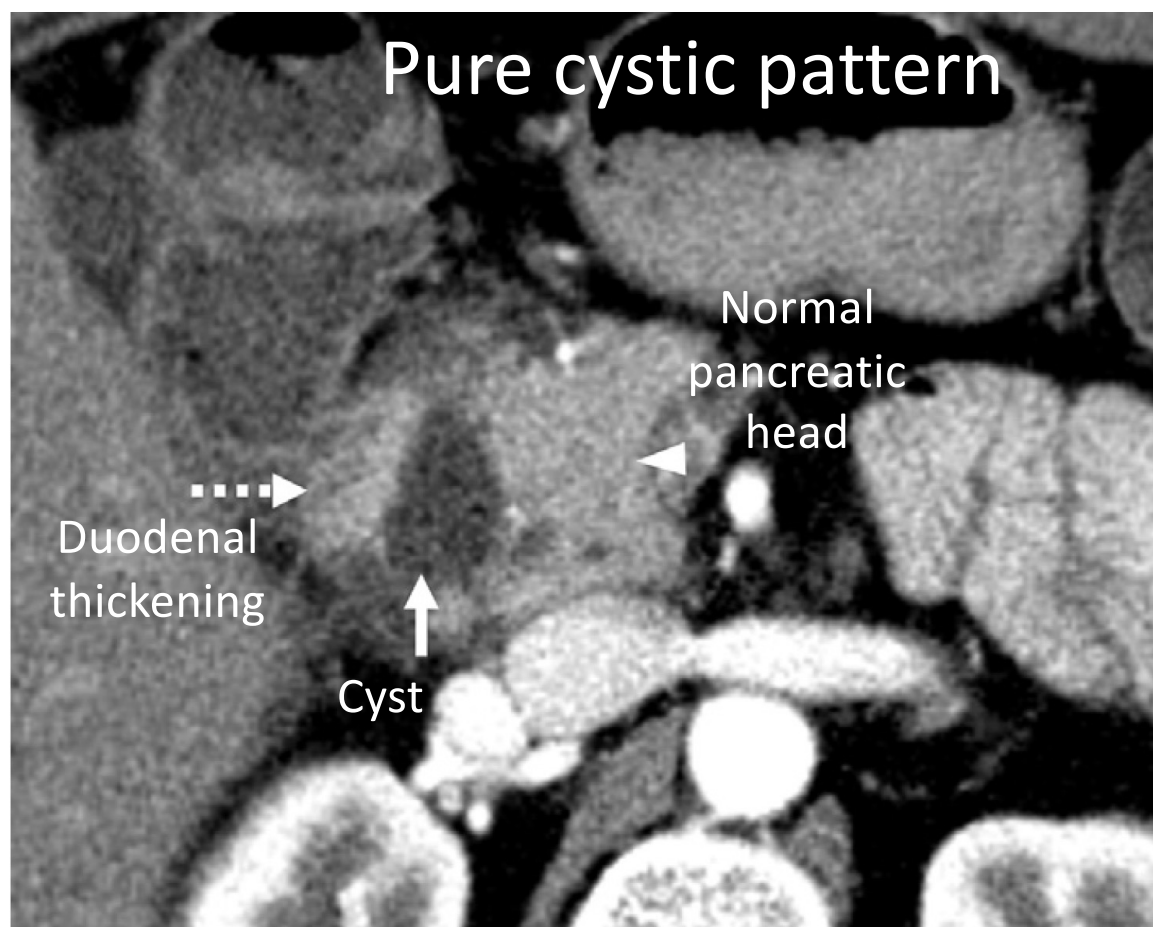


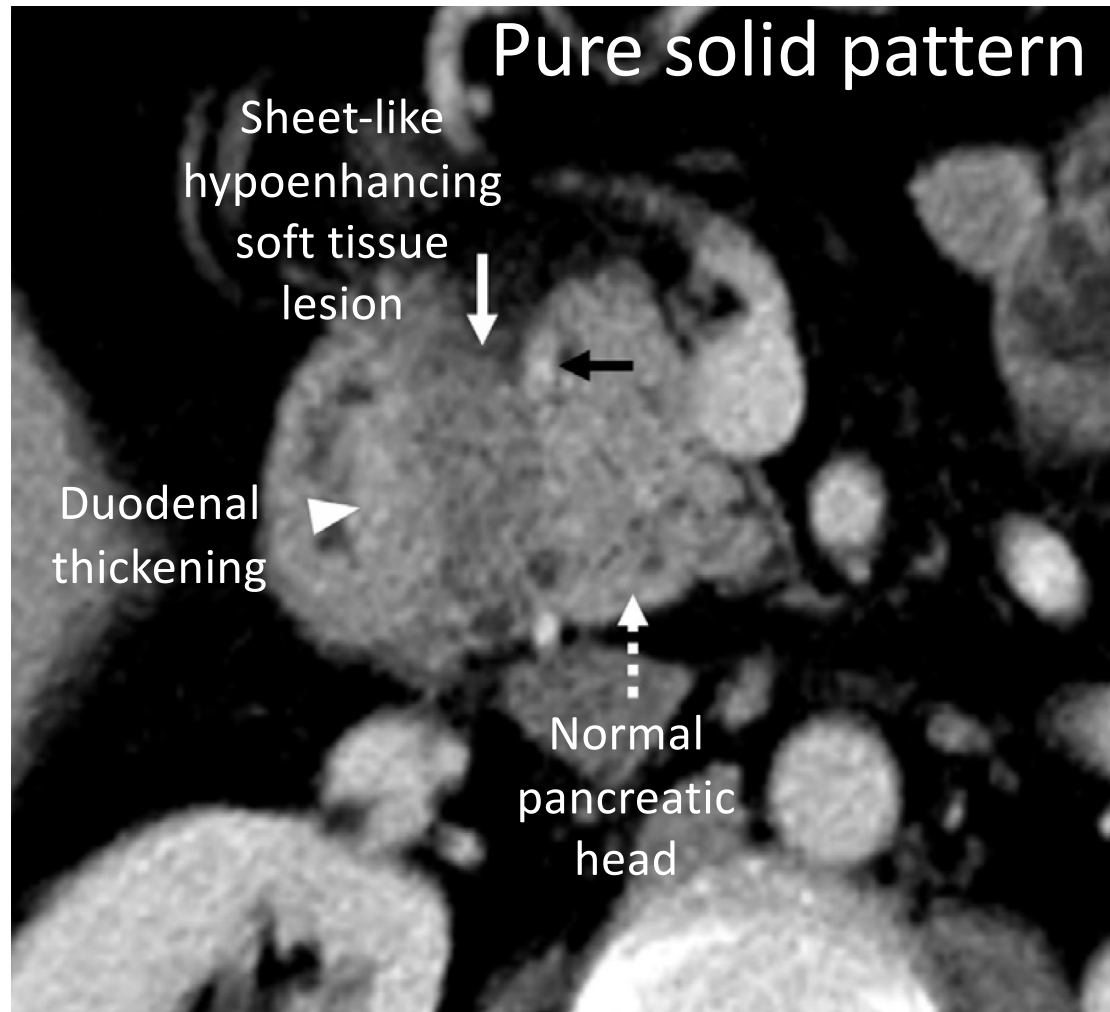
UNIVERSITAS
Miguel Hernández



E de-Madaria

CLINICAL FEATURES





Pancreatic gland with or without signs of chronic pancreatitis

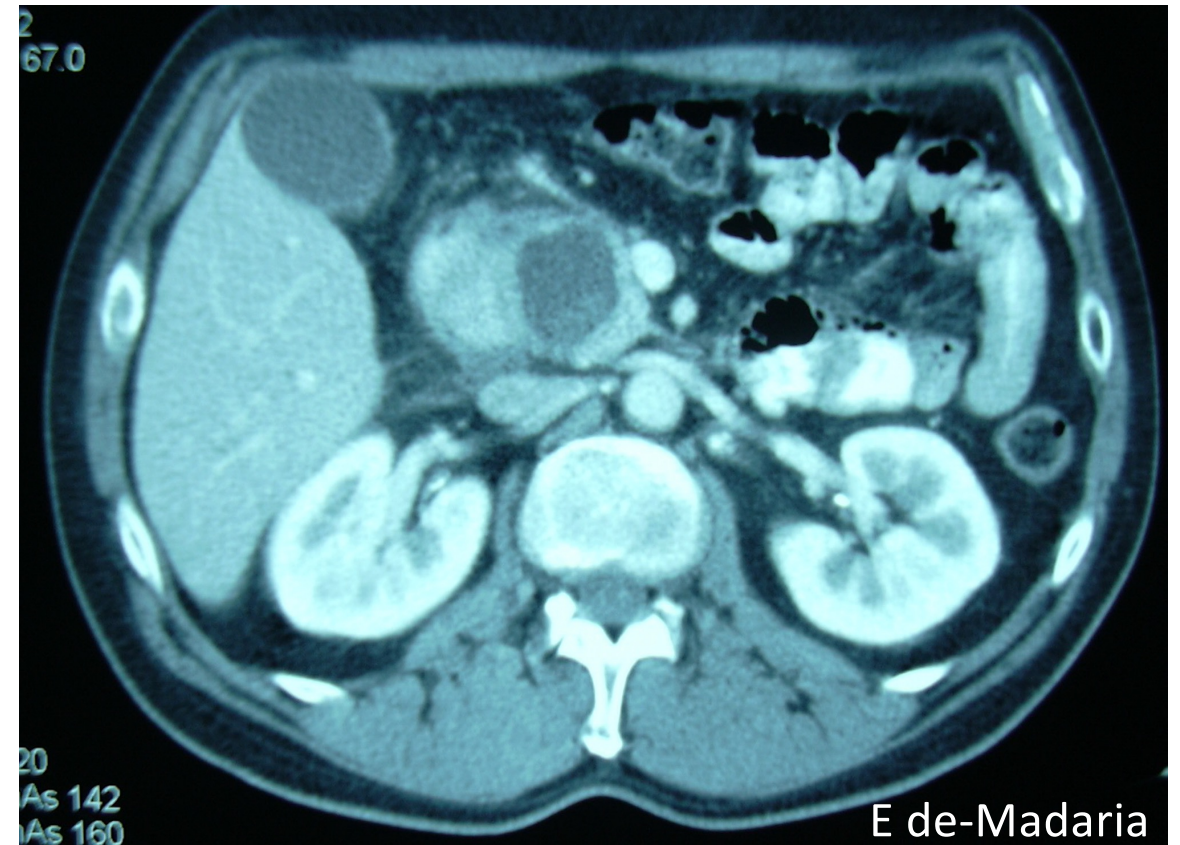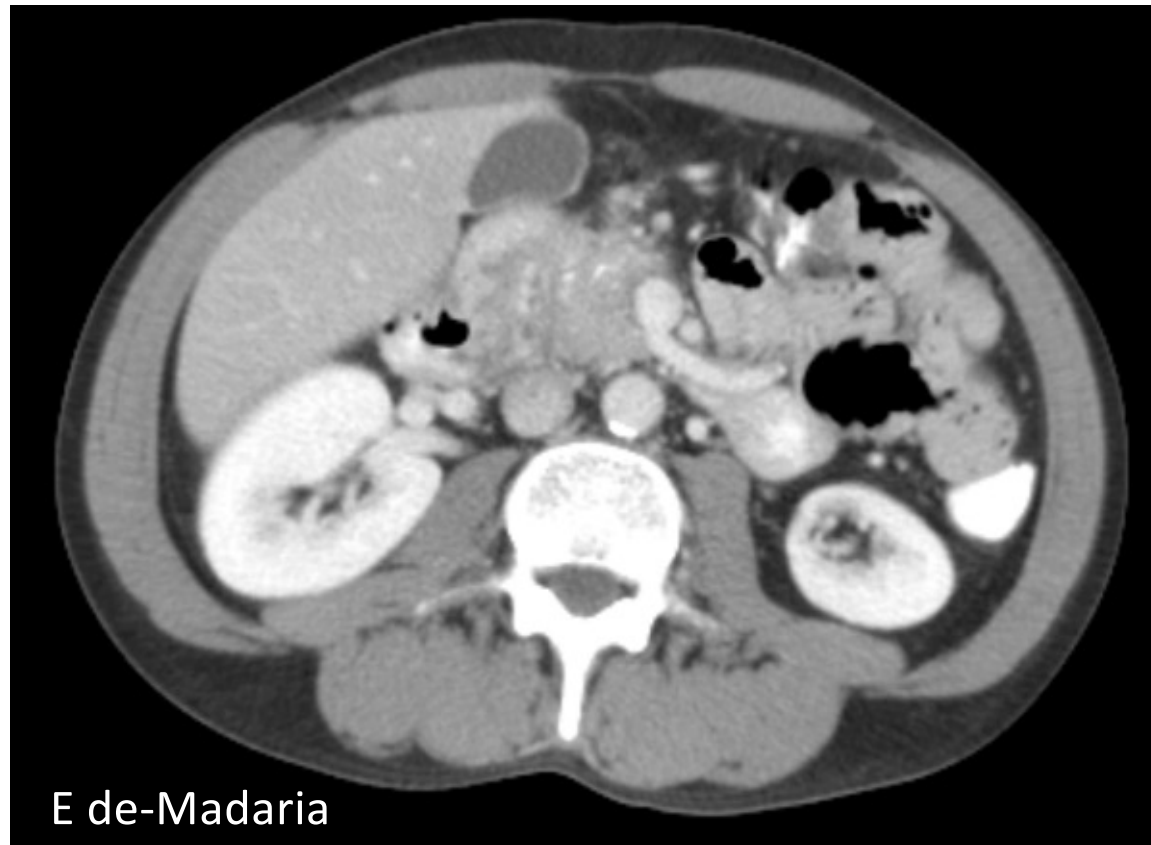
In favor of PDP (and not cancer):

Penetrating duct sign
CP-like upstream dilation of pancreatic duct

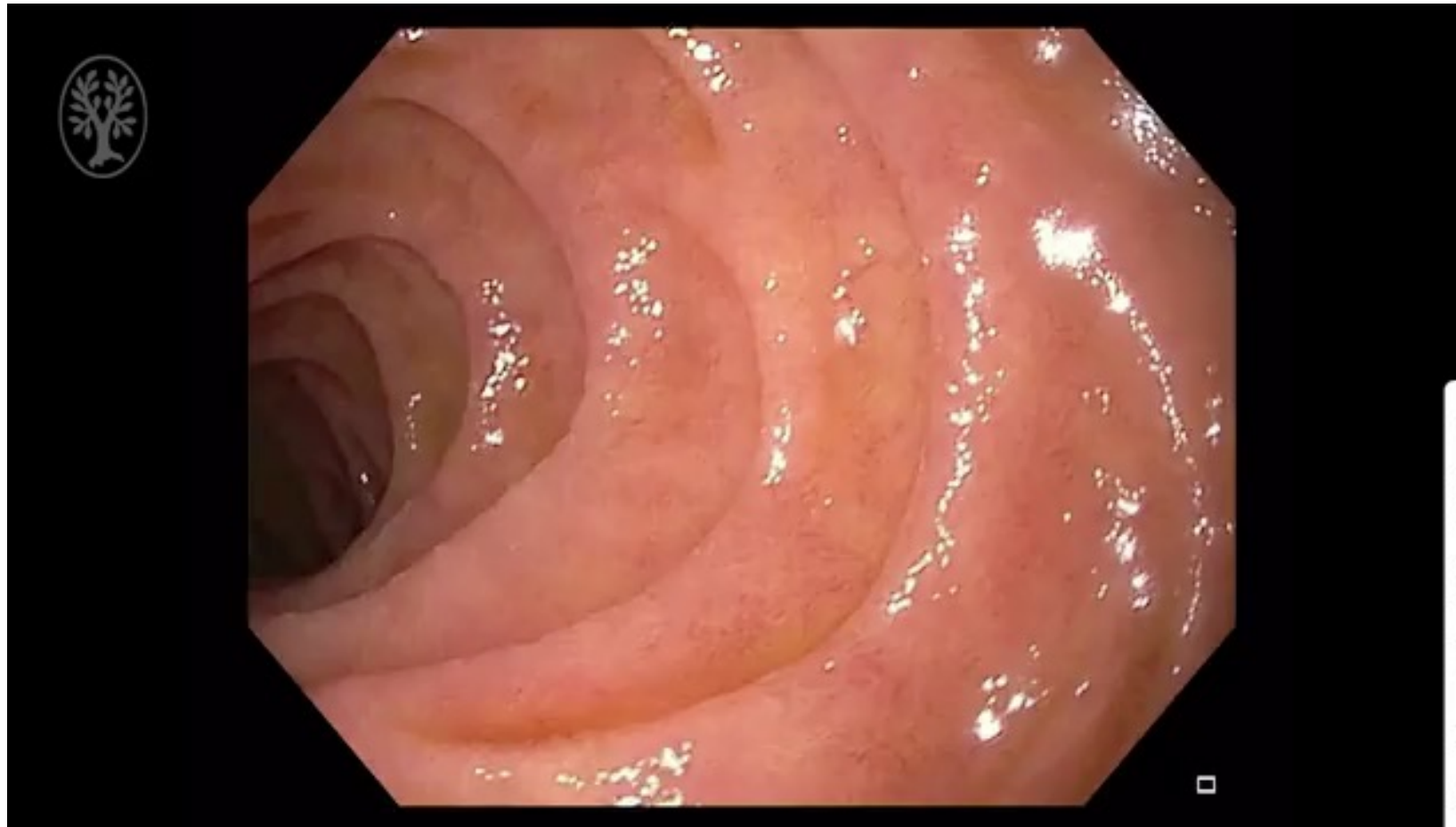
Smooth and tapered narrowing of the ducts

Vessel displacement, not encasement

DIAGNOSIS- CT MRI

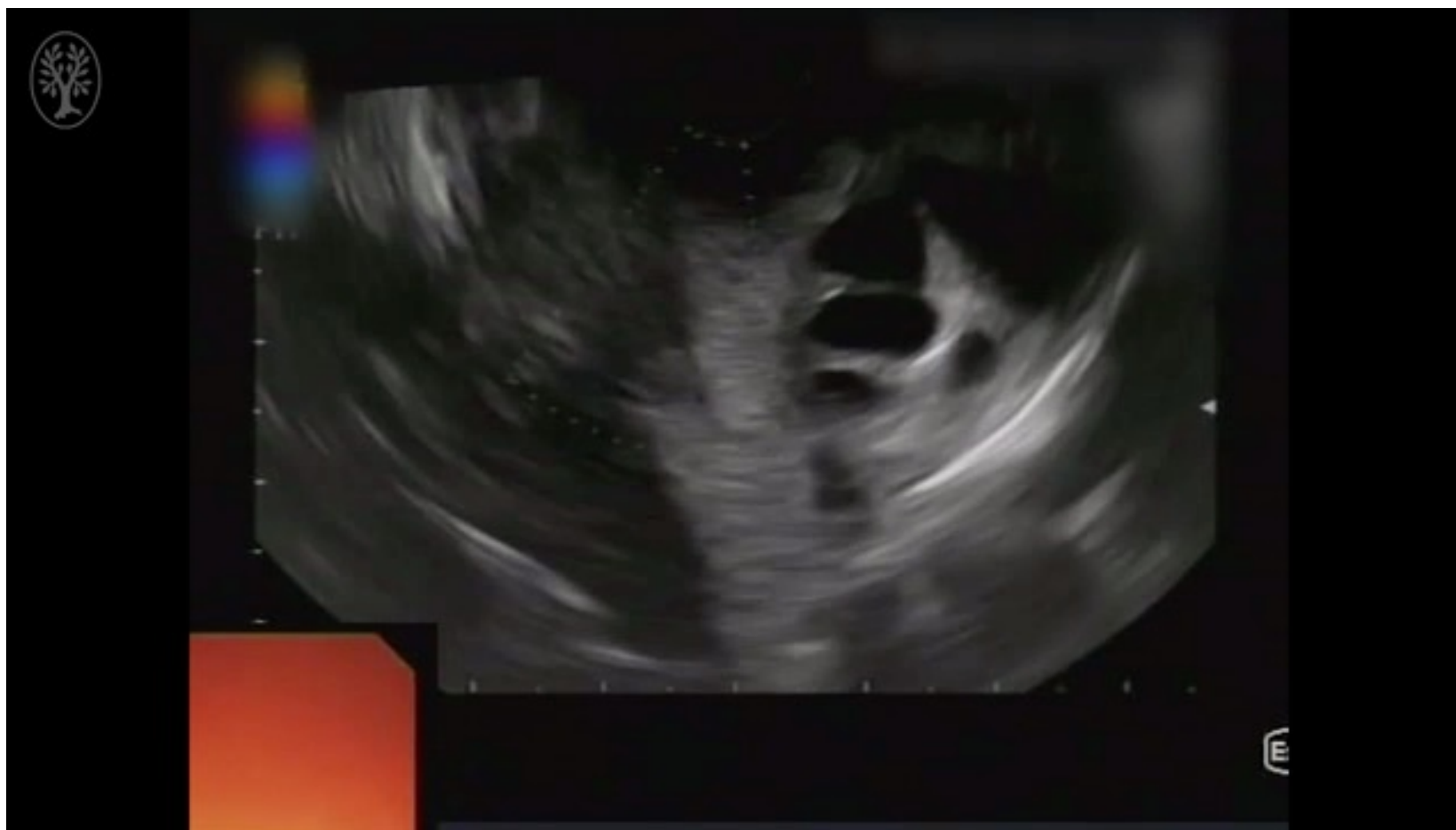

DIAGNOSIS- CT MRI



Pedro López-Muñoz, Vicente Pons,
Endoscopy 2022, with permission

DIAGNOSIS-Endoscopy



Dario Ligresti et al, Endoscopy
2019, with permission

DIAGNOSIS-Endoscopy

Jaundice

Gastric
outlet
obstruction



MANAGEMENT

Systematic Review

335 cases

90% male

87% smokers

87% alcohol cons.

92% abdominal pain

29% conservative (complete relief 50%)

12% endoscopy (complete relief 57%)

59% surgery (complete relief 79%)



Conservative management

Avoid smoking-alcohol
Analgesics, supportive measures
Role of somatostatin analogs?

MANAGEMENT



Endoscopic management

- Stenting of main bile duct
- Stenting of the main pancreatic duct
- Stenting of the minor papilla?
- Duodenal cyst drainage

MANAGEMENT



Surgical management

Mainly Whipple procedure
Highly effective but associated to morbidity
(20%)-mortality (1.5%)

MANAGEMENT

CONCLUSIONS

Paraduodenal pancreatitis involves the groove region as well as ectopic pancreatic tissue in the duodenal wall

Males, smokers, high alcohol consumption

Pain, gastric outlet obstruction, jaundice

Initial conservative/endoscopic management

Surgery in selected cases