

Minimally Invasive and Novel Therapeutics (M.I.N.T.) in Foregut Disease
September 29th -October 1st 2022

Esophageal Lengthening (Collis Gastroplasty)

Hany Takla, MD, FACS, FASMBS

| **Wentworth-Douglass Hospital**



Agenda

What is Short Esophagus?

Etiology of SE

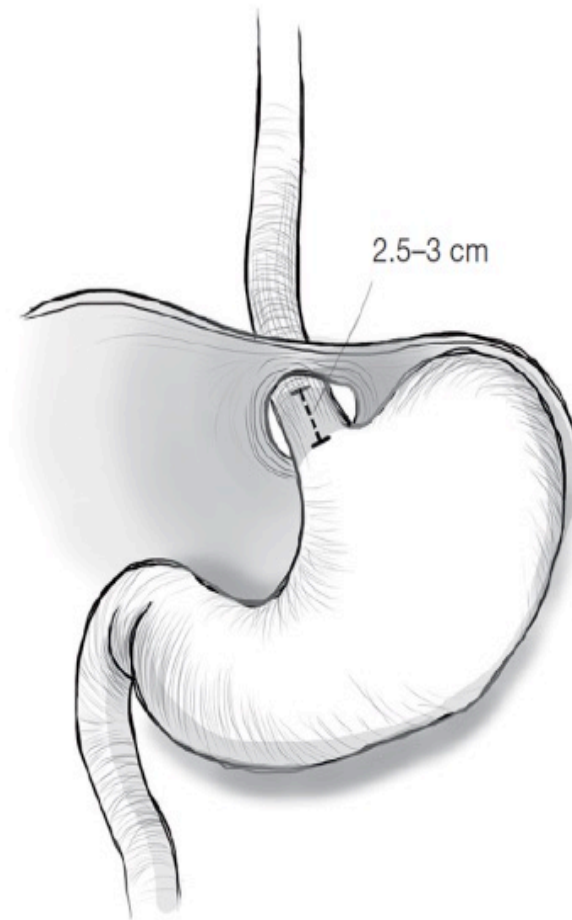
Does it exist ?

Is there a way to anticipate it?

Surgical technique

Video presentation

What is Short Esophagus ?



Etiology

GERD

Large paraesophageal hernia

Scleroderma

IBD

Caustic ingestion



Does it Exist?

- Wide range reported in Literature 0-60%
- High volume MIS centers 3-20%

Is there a way to predict it?

- Long h/o GERD, Previously failed Antireflux procedure
- UGI (5cm or more HH, Type III, IV)
- EGD (GE junction >5cm above hiatus, Grade 3,4 esophagitis, Barrett's)
- Manometry (No High pressure zone, hypo/A-peristalsis)
- Esophageal Length Index (ELI)
- Intraoperative?



Different Surgical Techniques for lengthening

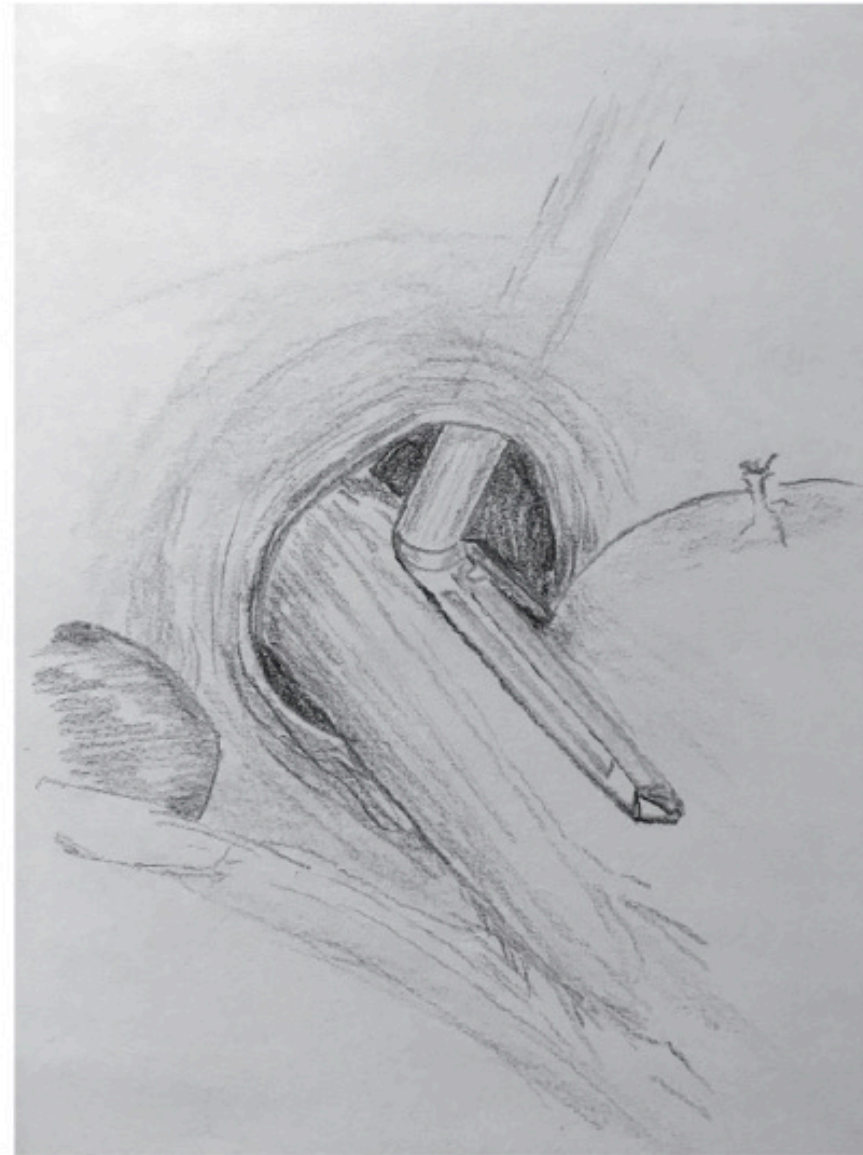
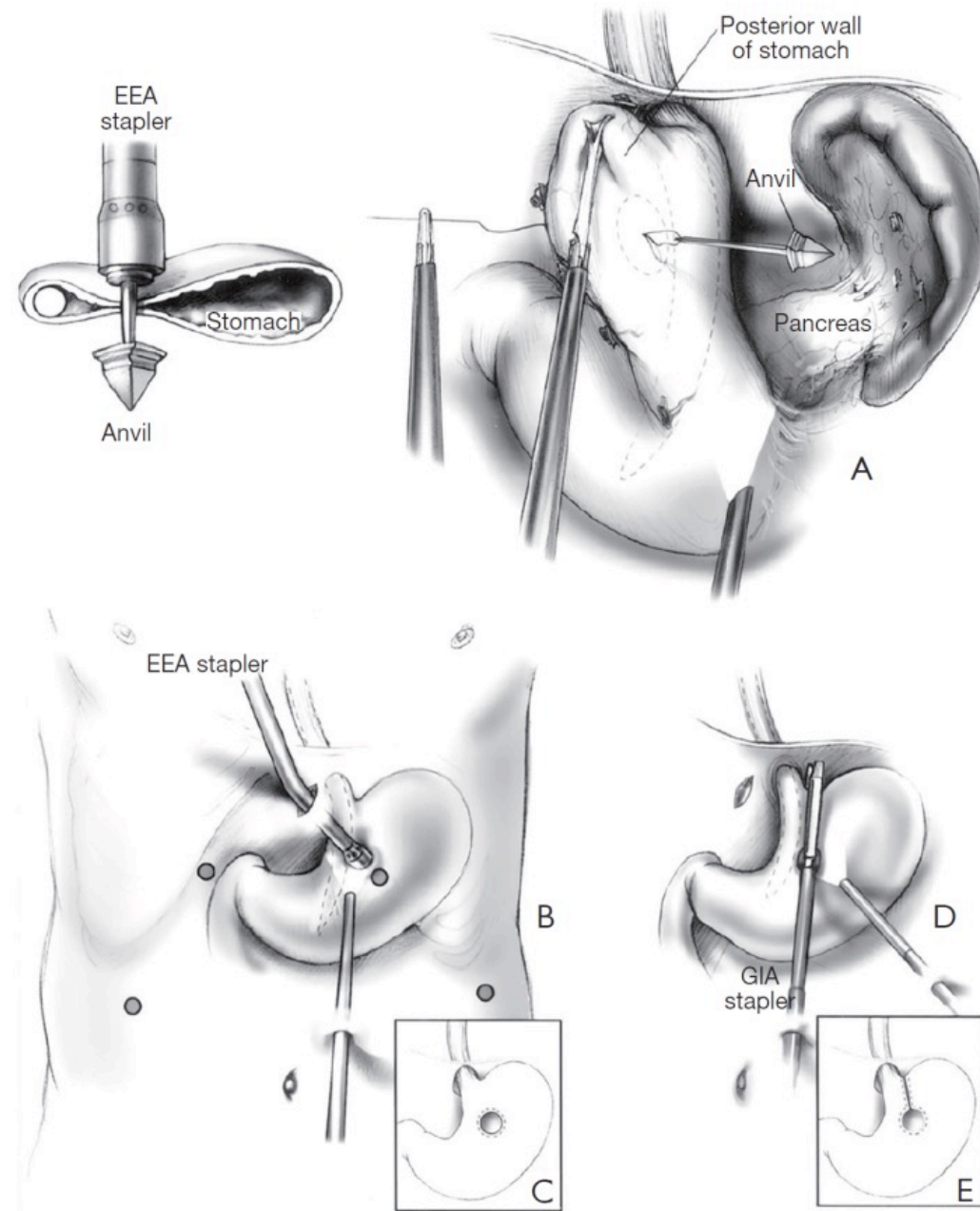


Figure 2 The combined thoracoscopic/laparoscopic technique is usually done via the left chest using an articulated stapler. It has the advantage of needing only a single firing of the stapler. (Used

Technique



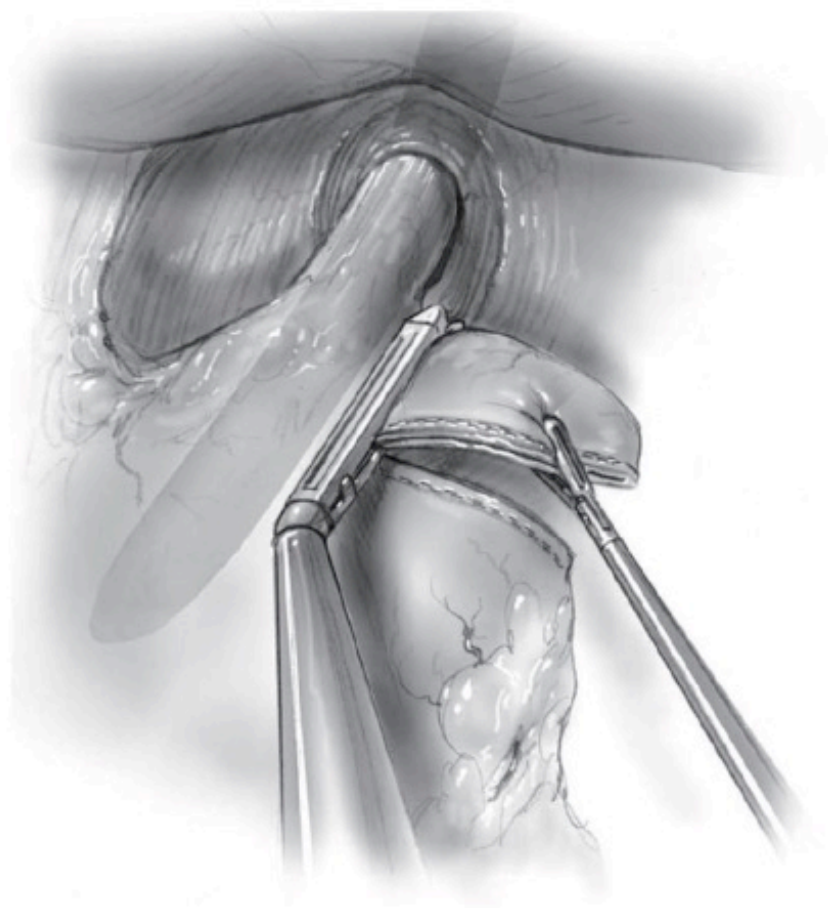


Figure 4 The “WF” is a totally laparoscopic approach that involves multiple applications of an articulating stapler. WF, wedge fundectomy. Used with permission from (17).

Video

HOLLYWOOD

PRODUCTION

Thank you

