

Minimally Invasive and Novel Therapeutics (M.I.N.T.) in Foregut Disease
September 29th -October 1st 2022

Approach to the refractory stricture

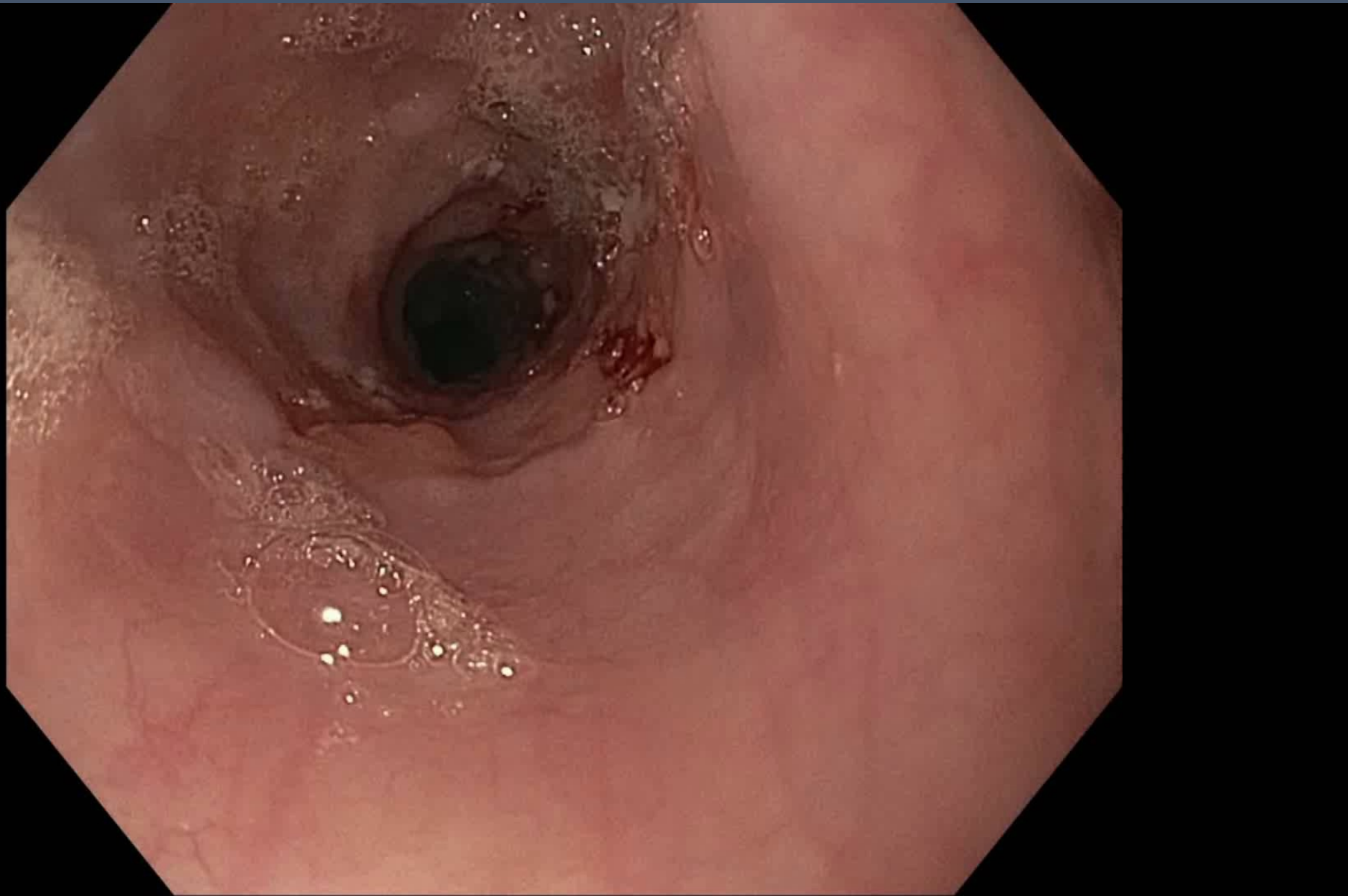
Kumar Krishnan MD

Massachusetts General Hospital



1. Stricture that you cannot get the smallest gastroscope through?
2. Stricture that you cannot safely dilate (ulcer, inflammation, location, etc.)
3. Stricture that does not respond to balloon dilations (how many,)
4. Stricture that despite dilating with balloon, savary, advanced strategies does not result in adequate relief of dysphagia





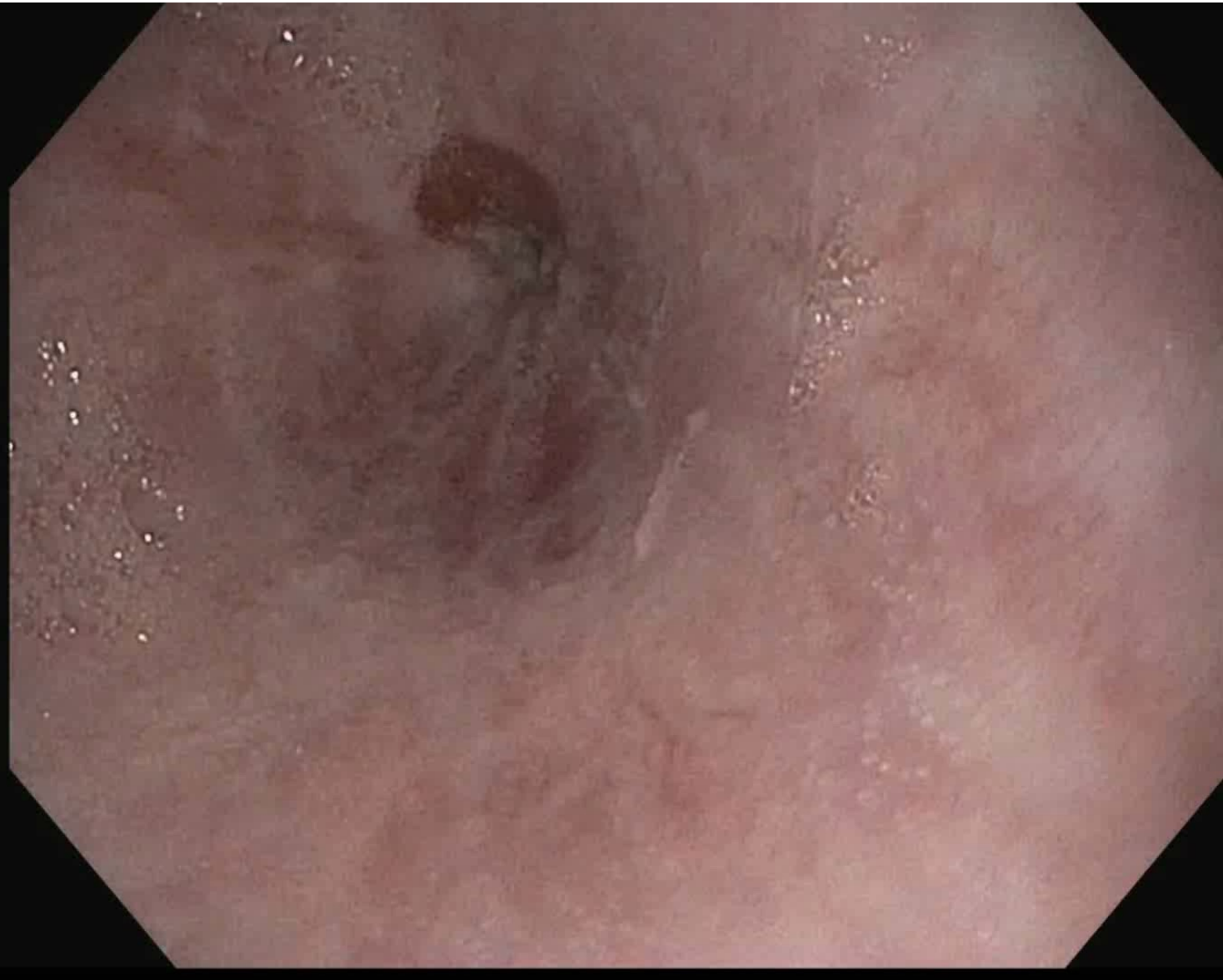Olympus HQ-190
Lugol Stain 2%
Spray catheter

68 yo with prior lymphoma, XRT, SCT. Now with progressive dysphagia
EGD with mid esophageal stricture. Scope dilation x 1 and savary dilation to
24Fr. Still with ongoing dysphagia.



HARVARD
MEDICAL SCHOOL





Olympus HQ 190
gastroscope

Hydrostatic dilator

BSC Wallflex 18mm x 120
cm covered metal stent

MERIT 19mm x 12cm
covered metal stent

Overstitch

55 yo with refractory stricture. Had severe episode of vomiting, and since then has noted dysphagia to solids and even some liquids. Underwent EGD with dilation x 2 at OSH. Referred to MGH for further treatment

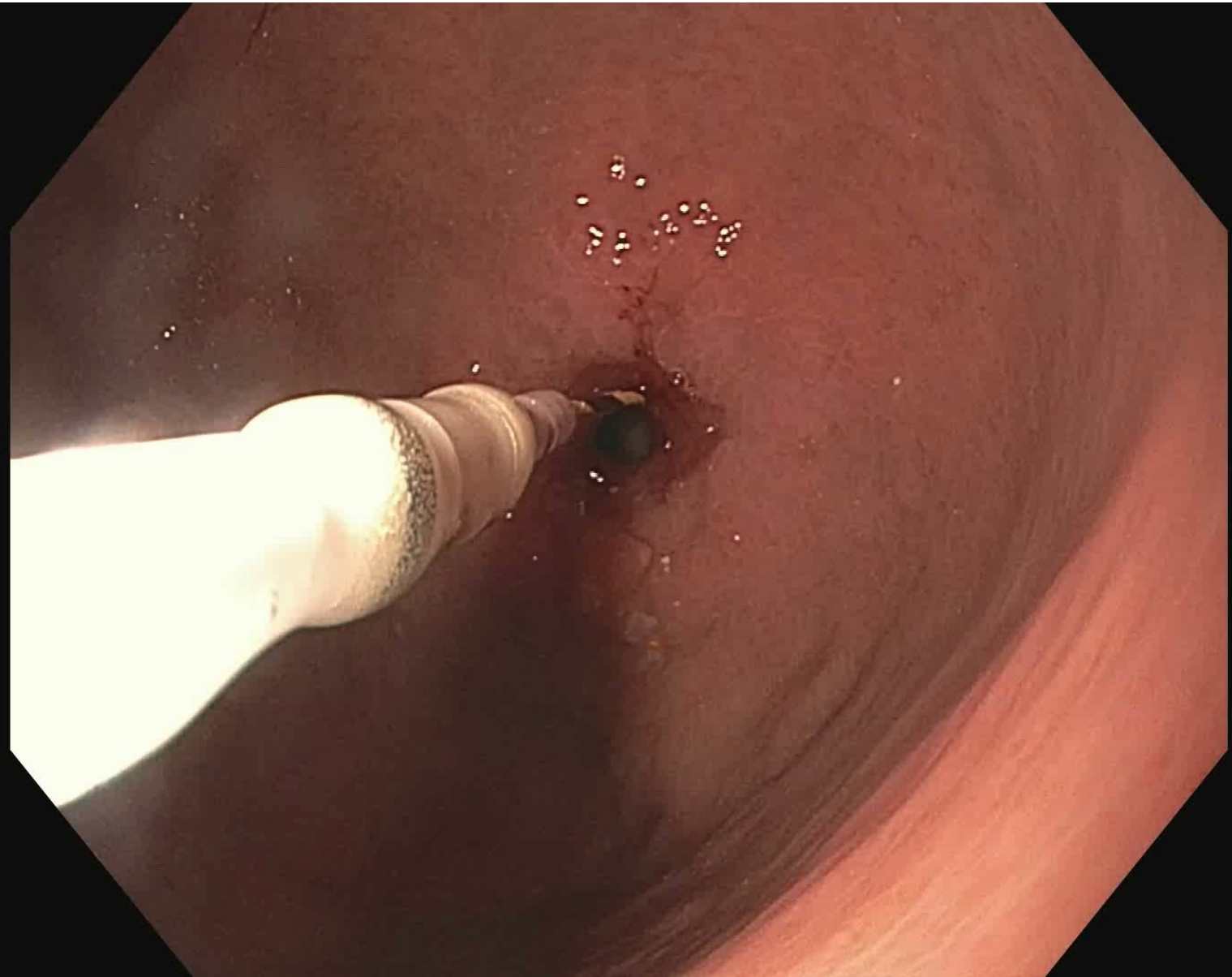
Olympus HQ 190
gastroscope

CRE dilator

Medtronic TTS ablation
catheter

60 year old with progressive upper esophageal dysphagia. He underwent two endoscopies with savary dilation, then referred for ulcer and refractory stricture. He has many self limited food impactions requiring regurgitation





Olympus HQ-190

TGF-UC 180J

Balloon catheter

0.035 Jagwire

20mm Axios stent

Overstitch system

16 year old with progressive inability to tolerate PO . History of gastric resection and now with stricture at the anastomosis

To treat a refractory stricture, you need to know why it is refractory
Malignancy, extrinsic, or simply an excessive fibrotic stricture

Understand the full breadth of endoscopic therapies

Stents: great if worried about perforation. Poorly tolerated

Use smaller size and don't forget to overstitch!!!

Needle Knife is great for anastomotic.

Understand when surgery is the right answer

Malignancy

Extrinsic