

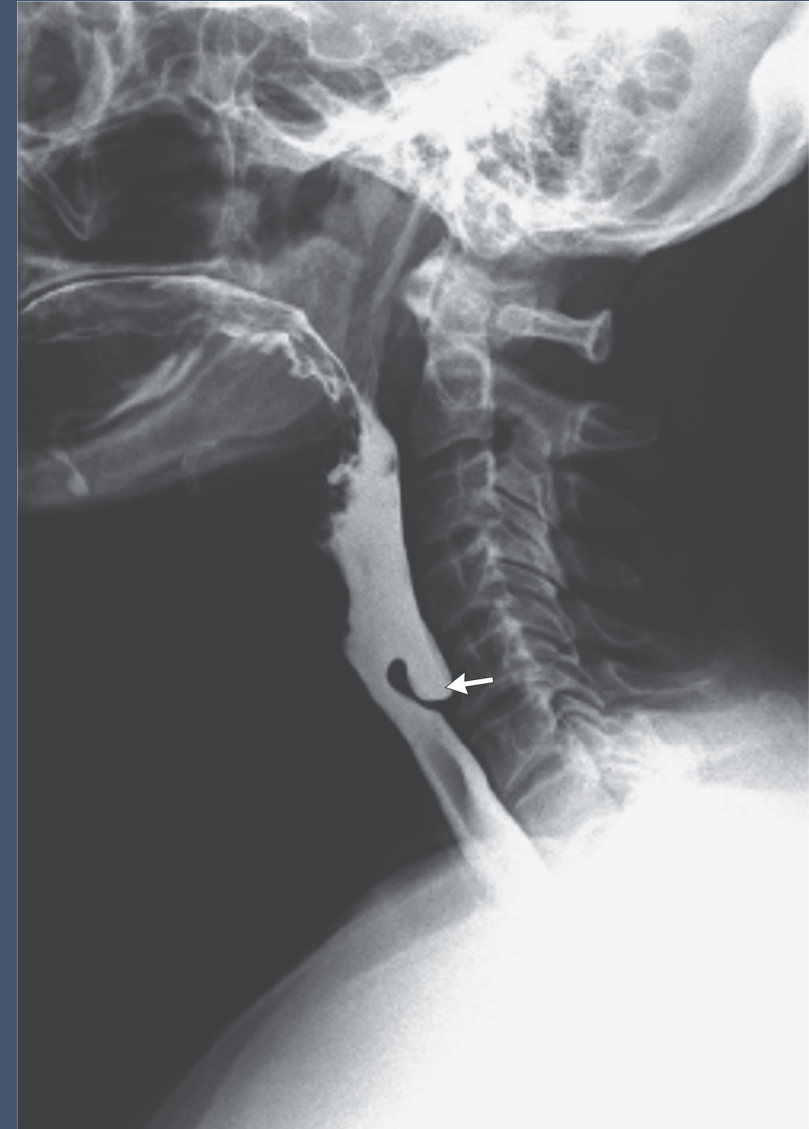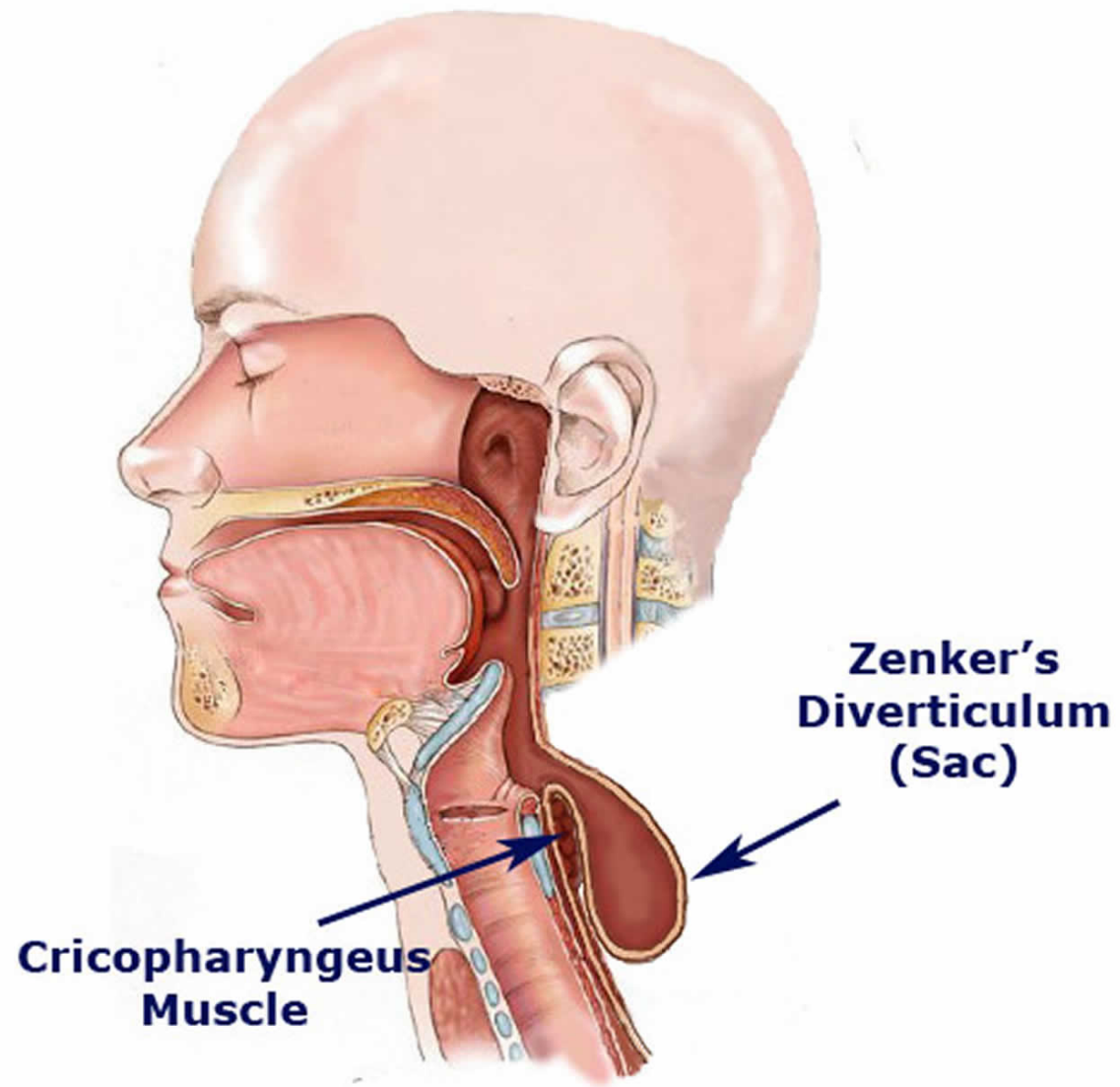
Minimally Invasive and Novel Therapeutics (M.I.N.T.) in Foregut Disease
September 29th -October 1st 2022

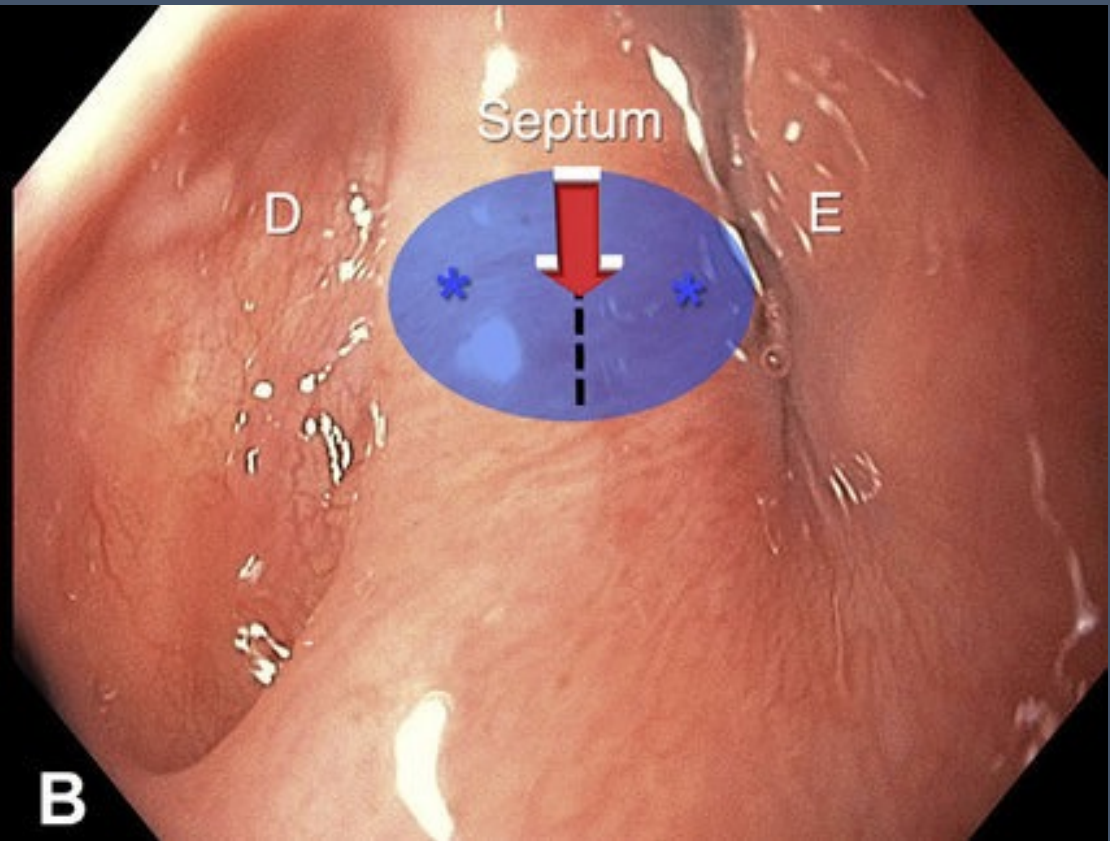
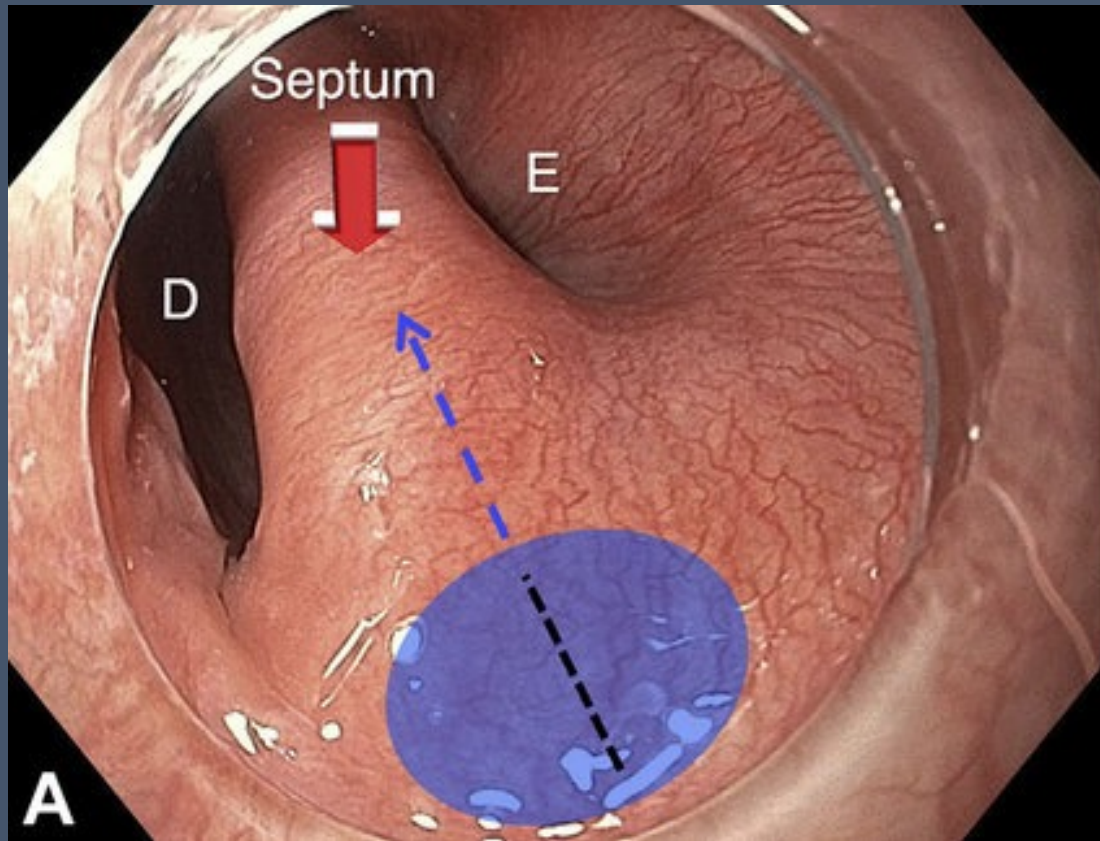
Zenker peroral endoscopic myotomy (Z-POEM)

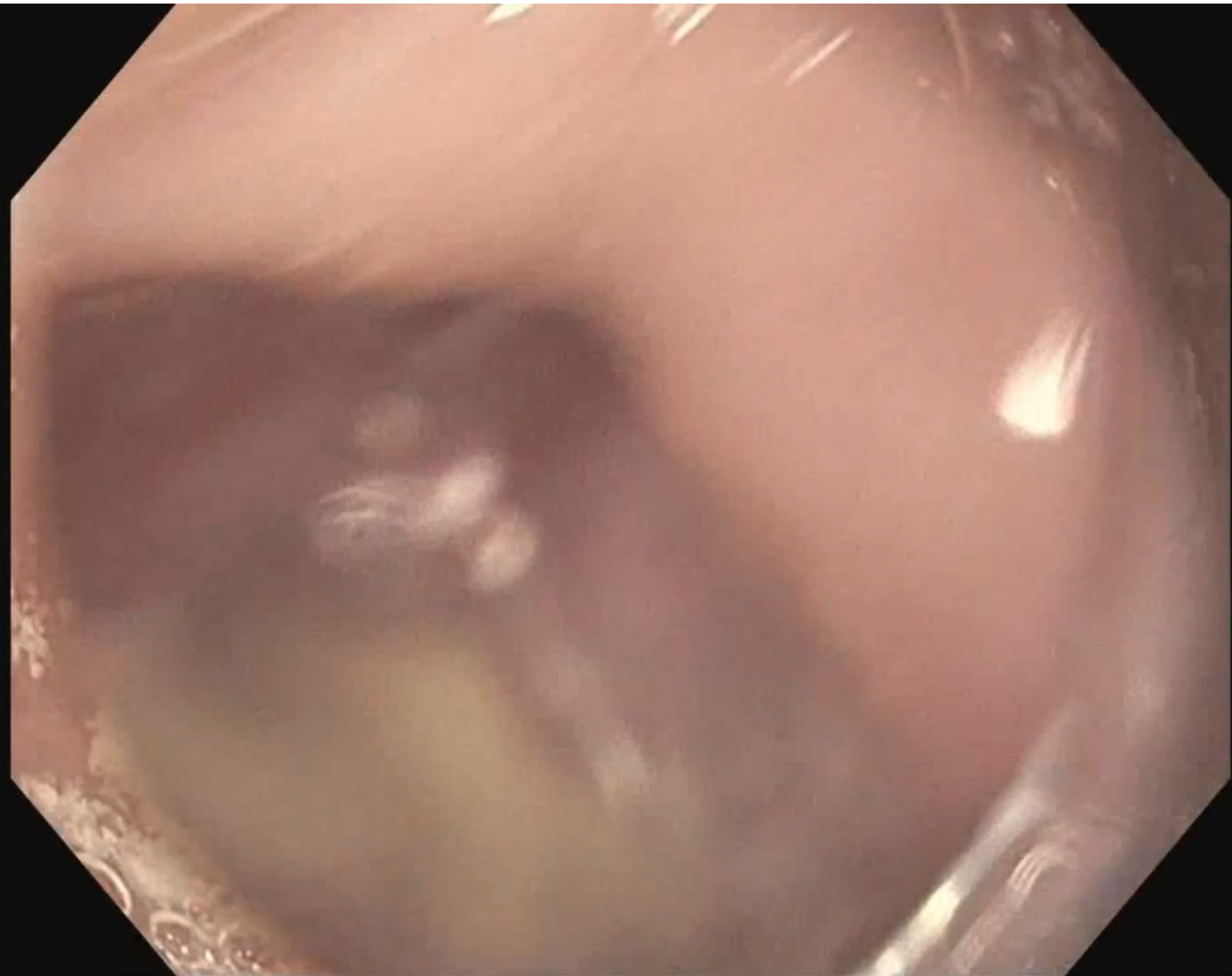
Kumar Krishnan MD

Massachusetts General Hospital









Scope:

Olympus H190

Tools:

Distal attachment cap

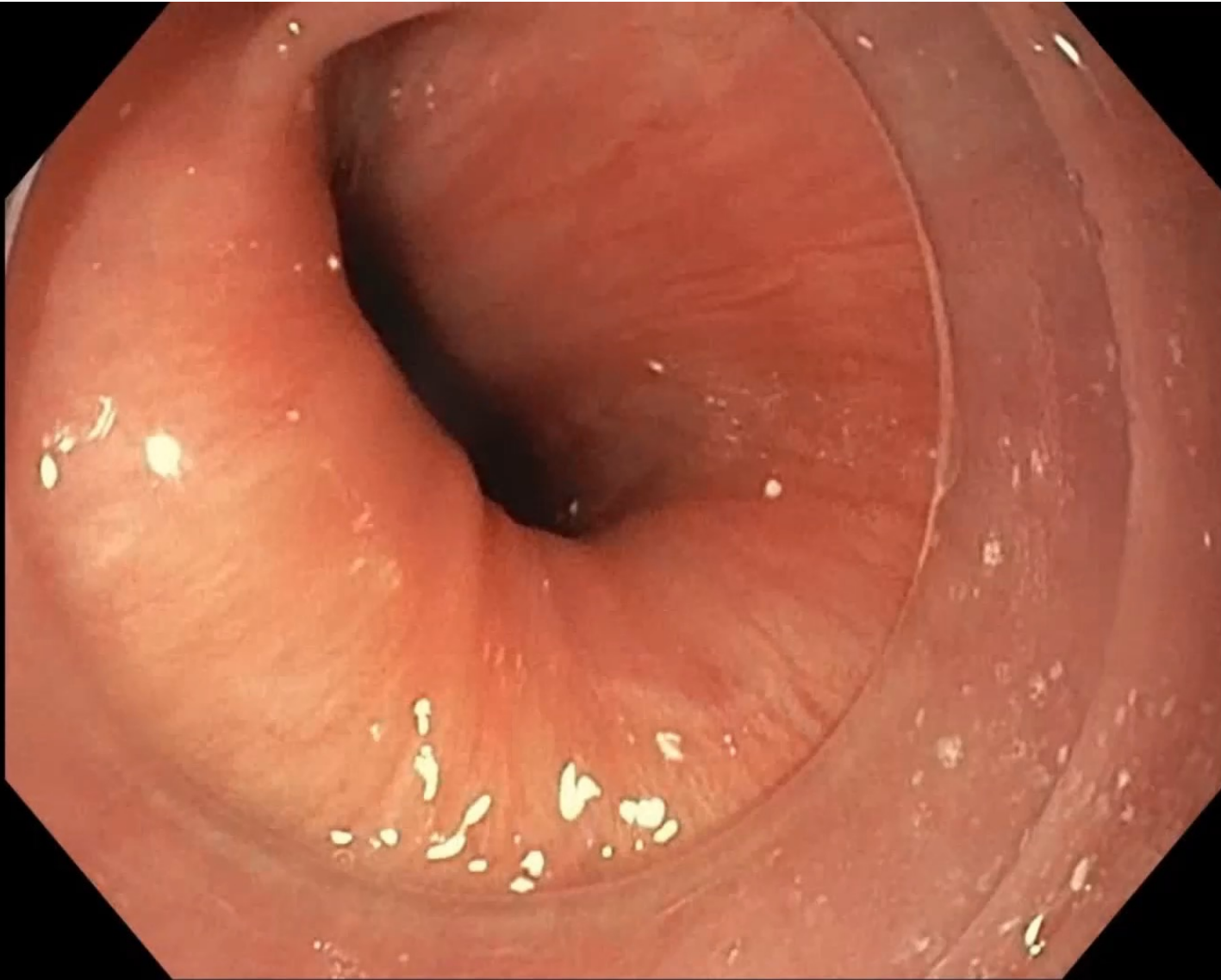
ERBE I type knife

(Endocut I

(Forced coagulation)

Soft coagulation

Duraclip 11mm

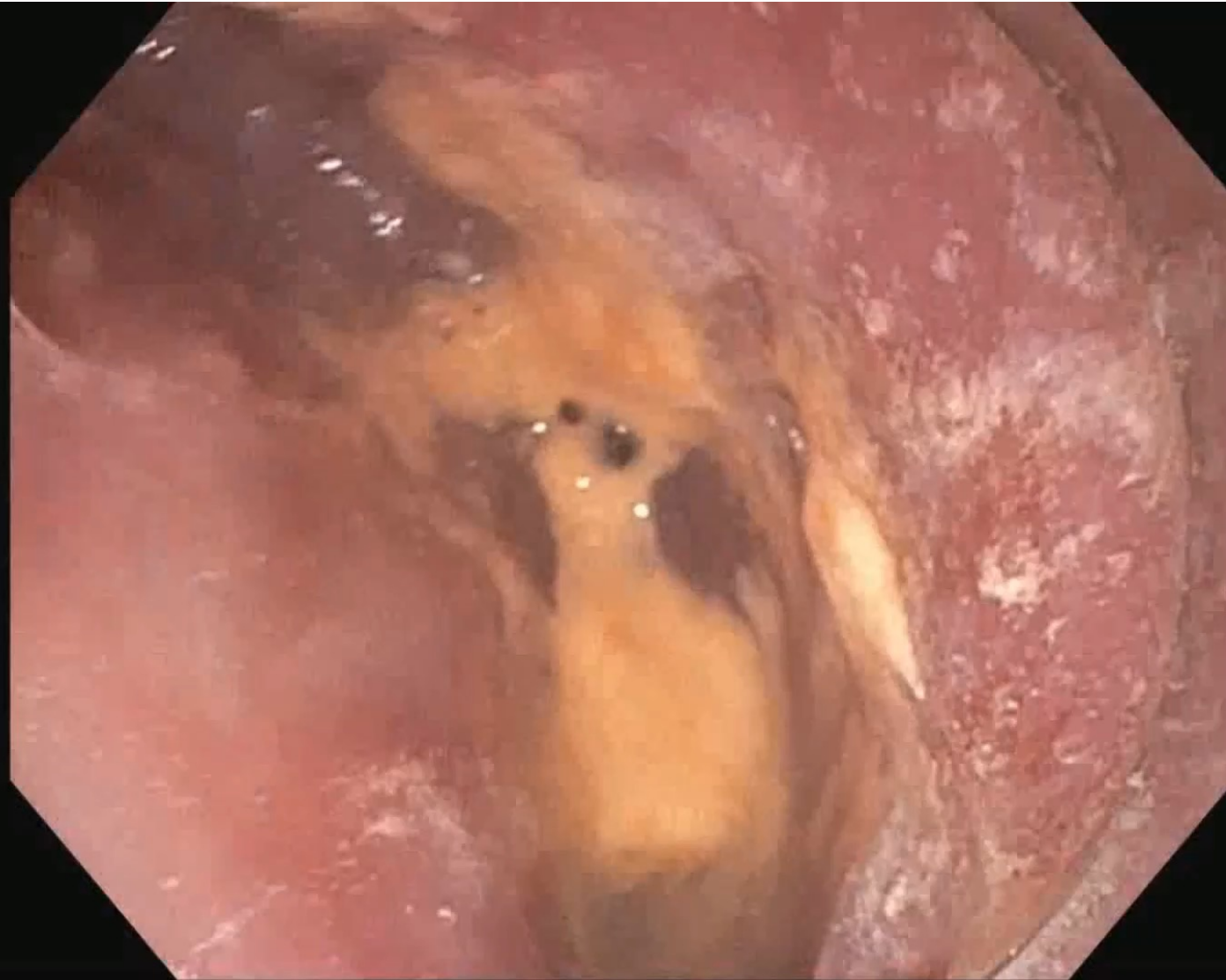

Pearls:

Carefully examine the Zenker pouch

Ensure no malignancy or cervical plate

Multidisciplinary discussion when you develop a “Secondary Zenker”



Pearls:

Recurrent symptoms will happen

Redo Z-POEM is definitely safe and effective

Be prepared for more fibrosis, more bleeding and less clean planes

Make sure to divide the muscle on the esophageal side

1. Take your time and dissect out anterior and posterior to the CP
2. Don't start the myotomy until you have clear landmarks
3. Advance myotomy few centimeters into the esophageal side
4. Go slow with diet advancement

